

Pediatric Acute Compartment Syndrome

Christopher D. Souder, MD¹; Scott Yang, MD²; Dustin A. Greenhill, MD³; Phillip K. McClure, MD⁴;
Matthew D. Ellington, MD¹

¹Central Texas Pediatric Orthopedics, Dell Medical School/The University of Texas at Austin, Austin, TX; ²Oregon Health and Science University, Portland, OR; ³Drexel University College of Medicine, St. Christopher's Hospital for Children, Philadelphia, PA; ⁴International Center for Limb Lengthening, Sinai Hospital of Baltimore, Baltimore, MD; Central Texas Pediatric Orthopedics, Dell Medical School/The University of Texas at Austin, Austin, TX

Abstract:

Pediatric acute compartment syndrome (PACS) is a rare but potentially limb threatening entity. The prompt recognition and emergent treatment of developing compartment syndrome is imperative to prevent lifelong disability. It can often be difficult to make a clinical diagnosis of acute compartment syndrome in the pediatric age group. This article seeks to provide an overview on how to appropriately diagnose and treat PACS.

Key Concepts:

- Early diagnosis should be suspected based upon the 3 A's (Anxiety, Agitation, increasing Analgesic requirements).
- The most common locations of compartment syndrome are in the lower leg and forearm with the most common cause being trauma.
- Prompt diagnosis and treatment of PACS is paramount to a good outcome.
- Most wounds can ultimately be closed with delayed primary closure.

Introduction

Acute compartment syndrome (ACS) following an injury can be devastating. Prompt diagnosis and treatment is crucial to decrease the burden of the disease. It was initially described in 1881 by Dr. Richard von Volkmann as an ischemic muscle contracture caused by external pressure leading to irreversible muscle necrosis most frequently seen in children.¹ Although similarities exist in the pathophysiology and treatment of acute compartment syndrome in adults and children, there are significant differences, most notably in the diagnosis. It has been taught that the 5 P's (Pain with passive stretch, Pallor, Paresthesia, Pulselessness, and Paralysis) are classic *signs* for established compartment syndrome. Many

would suggest that if the limb became paralyzed without pulses, that early diagnosis was missed, and residual morbidity is likely. *Signs* such as distal paresthesias and pain with passive stretch occur earlier in the process and prompt fasciotomy based on these may limit subsequent morbidity. Bae et al. evaluated a means to make an even earlier diagnosis based upon *symptoms*. In children, impending compartment syndrome is suspected by the three A's (Anxiety, Agitation, increasing Analgesic requirements).

The purpose of this paper is to provide an updated, comprehensive review of pediatric acute compartment syndrome (PACS) focusing on the epidemiology, diagnostic

challenges, treatment, wound management, complications, and finally, prophylactic treatment for surgeries that have a higher risk of postoperative compartment syndrome.

Diagnosis of ACS

A timely diagnosis of PACS is important to prevent irreversible muscle damage from ischemia which can occur as early as 4 hours from the onset of elevated compartment pressures.^{2,3} The time to fasciotomy clearly affects outcomes, as children who have had very prolonged time to fasciotomy for leg compartment syndrome (mean > 48 hours from injury) were more likely to suffer poor outcomes.⁴ Furthermore, a study of nontraumatic compartment syndrome in children in which delay in diagnosis was more common (median 48 hours to diagnosis) demonstrated high rates of myonecrosis (54%) at surgery and poorer outcomes.⁵ PACS specifically has been associated with a longer delay in diagnosis but children may still have good outcomes with delayed treatment.^{4,5,8} Flynn et al. found that delayed management of pediatric compartment syndrome can still be safely performed with a low risk of infection.⁴

The diagnosis of ACS in children remains a clinical diagnosis (Figure 1). In the pediatric population, the age and relative maturity of the child is a consideration in establishing the diagnosis of compartment syndrome. Pain is the most common presenting symptom of compartment syndrome in children,^{3,5} but assessing pain in children can be challenging. Astute observation is necessary when evaluating younger children who may not be able to clearly verbalize pain. A toddler who writhes around in bed and can't be distracted, who won't focus on TV or videos, or who just "isn't himself" may be developing early PACS. Particular attention must be given to increasing anxiety, agitation, and analgesic requirements.^{5,6} For example, a school age child with a forearm compartment syndrome may demonstrate complete unwillingness to participate in a neurovascular examination due to agitation. Observation of restlessness and pain behaviors as well as relative self-splinting of the fingers

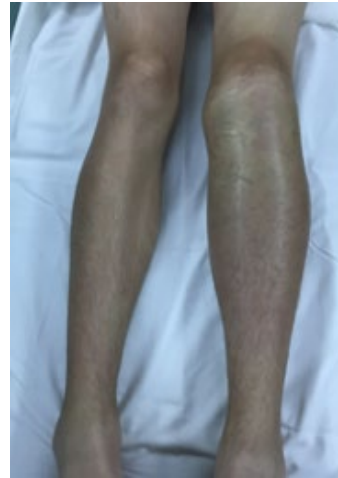

Figure 1. Clinical image of a 14-year-old male who developed compartment syndrome after sustaining a tibial tubercle fracture while playing football (Courtesy of Chris Souder, MD, Dell Children's Hospital, Austin, TX).

can be early indicators of impending compartment syndrome. Furthermore, increased vigilance should be maintained in children with fractures and associated nerve injuries. Nerve injury from displaced fractures can mask typical pain and allow a silent compartment syndrome to develop.⁷

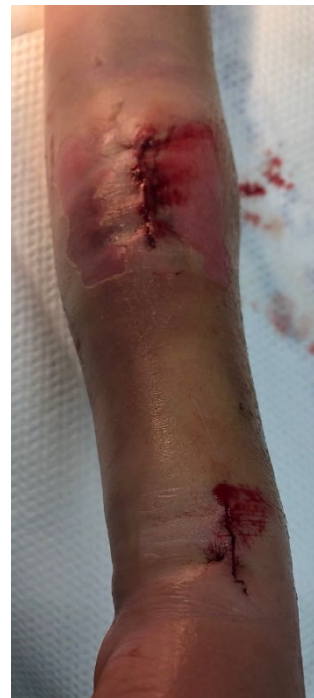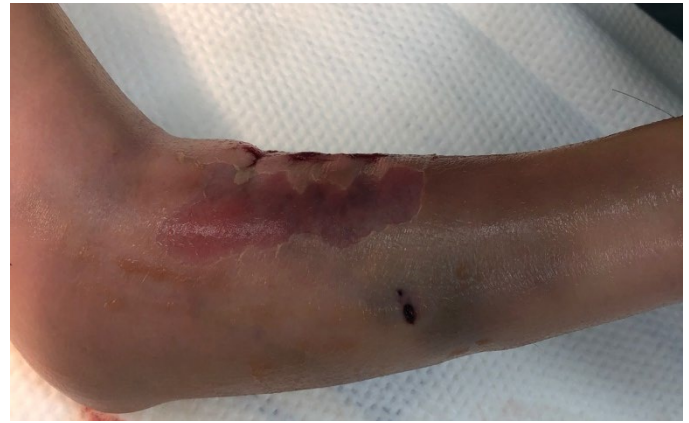The most commonly utilized adjuncts for identifying compartment syndrome are needle manometry, in which intracompartmental pressure is measured by the resistance of a small amount of saline solution injected into the compartment, and the slit catheter method, in which the needle pressure is measured with an arterial line transducer. Near infrared spectroscopy (NIRS) is a noninvasive method to measure muscle oxygenation via a sensor placed on the skin and may become a tool in the pediatric population. Studies in both adults and children have demonstrated that NIRS can be utilized to detect changes in perfusion to a muscle compartment, though lack of standardization threshold values for compartment syndrome makes this tool nondiagnostic at the present time.¹³⁻¹⁵

The accepted objective pressure values for compartment syndrome in both the adult and pediatric populations range from absolute compartment pressure of 30–45 mm Hg or less than 30 mm Hg from mean arterial pressure ($\Delta P < 30$ mm Hg).^{2,8,9,30} These values have been proposed as the threshold for developing muscle ischemia. Children have been demonstrated to have increased baseline lower leg compartment pressures as compared

to adults,^{10,11} though this finding has not been interpreted to accept higher compartment syndrome thresholds in children. When using 40 mm Hg as a threshold for fasciotomy for pediatric forearm fractures, Royle found that no forearm fractures under the threshold developed sequelae of compartment syndrome.¹² Needle manometry or slit catheter methods are invasive for anxious children, and often are impossible to perform in an awake child. Hence, the diagnosis of compartment syndrome and the decision to pursue fasciotomy rests mostly on clinical assessment. The diagnosis can be supported via compartment pressure measures after the child is anesthetized and prior to fasciotomy.

Epidemiology

The most common cause of acute compartment syndrome in children is trauma with associated fracture.¹⁸ Amongst those patients who sustained trauma, older age (adolescent group) and firearm or motor vehicle collision mechanisms have been demonstrated as an increased risk factor for developing compartment syndrome.^{17,18} Other causes of acute compartment syndrome include infection, snake or insect bites, vascular injuries or venous infiltration, coagulopathy and bleeding disorders, and iatrogenic causes such as prolonged awkward limb positioning during surgery.³ In a review of 233 children with compartment syndrome of any extremity, 65% presented with fractures. The lower leg and forearm accounted for 87% of all cases of compartment syndrome.¹⁶ The incidence of PACS in tibial shaft fracture ranges from 3–11.6%,^{18,19} in which a motor vehicle injury mechanism was noted as a risk factor. There are several known scenarios for which compartment syndrome of the upper extremity can be of potentially increased risk, including severely displaced supracondylar humerus fractures with vascular injury, as well as supracondylar humerus fractures associated with a displaced forearm fracture (i.e., floating elbow). In a series of nine children with floating elbow injuries where both the humerus and the forearm are displaced, 33% of patients developed compartment syndrome.²⁰ A subsequent study with more patients demonstrated a much lower rate of compartment



Figures 2a and 2b Clinical image of an 8-year-old girl who developed compartment syndrome after flexible intramedullary nails were placed for an open both bone forearm fracture (Courtesy of Matthew Ellington, MD, Dell Children's Hospital, Austin, TX).

syndrome in floating elbows of only 2%,²¹ though caution is advised in this particular injury given the higher rate of ipsilateral nerve injury²² and thus the potential for silent compartment syndrome.

Several small series have reported the development of compartment syndrome after flexible intramedullary nailing of forearm or tibia fractures. The incidence of compartment syndrome after flexible intramedullary fixation of pediatric forearm fractures ranges from 2–7.5%,²³⁻²⁵ (Figures 2a and 2b) with increased operative time and multiple attempts at reduction considered risk factors. Timing may also be an important factor. Children whose forearm fractures are fixed in a delayed

manner are less likely to develop ACS. For the tibia, Pandya et al. demonstrated a high incidence of compartment syndrome (19.3%) after flexible nailing of pediatric tibial shaft fractures, with weight of > 50 kg and complex fracture patterns being identified as risk factors.²⁶ These studies highlight the need for increased vigilance for compartment syndrome when increased trauma or manipulation to the extremity occurs whether through higher energy injury mechanism or during challenging surgical intervention. The wise surgeon will have a low threshold to open fractures in order to pass flexible rods as opposed to multiple attempts to closed reduce the fracture and pass nails.

Treatment

If there is concern for acute compartment syndrome, the provider must take measures to optimize the environment of the limb to increase limb perfusion and decrease pressure. These actions consist of moderate elevation of the limb to the level of the heart. Excessive elevation may decrease the arteriovenous pressure gradient and diminish perfusion.^{29,30} Any circumferential dressings and compressive casts or splints must be released to lessen pressure. Systemic hypotension should be prevented as this leads to decreased perfusion pressure to the extremity. Supplemental oxygen can assist in maintaining optimal saturation.³⁰

When the diagnosis of compartment syndrome has been made, emergent fasciotomy is indicated. The surgeon must remember the adage “*time is tissue.*” Excellent outcomes are commonly associated with early identification and treatment. Decompressive fasciotomies of each involved compartment are performed at the time of surgery. This consists of long skin incisions and wide fascial incisions. Muscles within the compartments are evaluated and, occasionally, release of individual epimysium is required if this is found to be constrictive. Obviously traumatized and torn muscle edges should be carefully debrided. In pediatric patients, muscles that are not mechanically disrupted but have questionable viability should not be debrided initially, as children possess an increased capacity for tissue recovery after injury.³¹

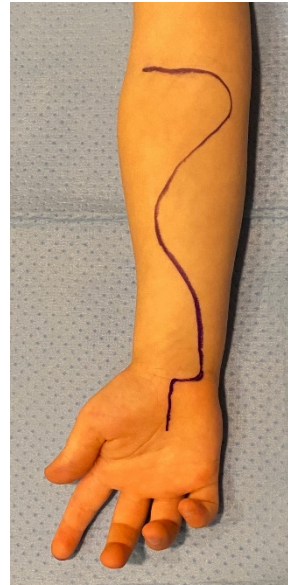

Figure 3. A complete forearm compartment incision is drawn here. The entire incision is needed if there is involvement to the carpal tunnel and if the brachial artery needs to be inspected. More often, the center portion of the incision is sufficient to decompress the volar compartment (Courtesy of Chris Souder, MD, Dell Children's Hospital, Austin, TX).

After decompression, the wound is left open and is covered with a sterile dressing or more likely with the use of VAC system. Typically, the patient returns to the OR in 48–72 hours for irrigation, inspection of the soft-tissues, and a strategy for closure is developed. Viability of the muscles is estimated by evaluating for the 4 C's: Color, Consistency, Contractility, and Capacity to bleed. Careful consideration is needed when assessing the muscles. Some would argue that if tissues “appear” nonviable as described above, these are sharply debrided. Yet in children, the zone of necrosis can be hard to define and removing the center of a muscle belly will remove continuity with the distal tendons and perhaps some more viable muscle that is proximal. As such, the focus is to get early wound closure primarily or coverage with a soft-tissue graft. The following outlines the site-specific approaches for fasciotomy in PACS.

Forearm

ACS in the upper arm is extremely uncommon and thus we will focus on the much more common scenario of ACS of the forearm and hand. There are three compartments within the forearm: volar, dorsal and the “mobile wad.” Most commonly, ACS affects the mobile wad and the superficial and deep volar compartments. As such, a curvilinear incision is used (Figure 3) to release the volar compartment as well as the mobile wad if indicated.

When a carpal tunnel needs to be released, the incision begins between the thenar and hypothenar eminences and then curves ulnarly along the wrist crease to avoid the palmar cutaneous nerve. It allows access to Guyon's canal if needed, and the flap provides coverage over the median nerve and flexor tendons. The incision proceeds proximally along the ulnar side of the forearm before curving radially at the midportion of the forearm. The incision can be carried across the antecubital fossa to a point anterior to the medial epicondyle if needed to explore the brachial artery. This incision will allow release of both the superficial and deep volar compartments as well as the mobile wad. Alternatively, the mobile wad may be approached with a dorsal incision or a direct incision overlying the compartment. Most often, the volar release adequately decompresses the forearm, including the dorsal compartment.³² The dorsal compartment is reevaluated after volar release, and if concern still exists, it is released as well. A longitudinal dorsal incision from the lateral epicondyle to Lister's tubercle is performed, and the dorsal compartment fascia is then released.

Hand

The hand contains 10 compartments: thenar, hypothenar, adductor pollicis, four dorsal interossei, and three volar interossei compartments. Four incisions can be used for release of all 10 hand compartments. Most commonly, hand compartment syndrome can be treated with two dorsal incisions centered over the second and fourth metacarpals. This allows access to the interossei and the adductor pollicis muscles with dissection around both sides of the second and fourth metacarpals. If indicated, thenar and hypothenar incisions can be made to release these compartments.

Thigh

The thigh is divided into three compartments: the anterior, posterior, and adductor compartments. These compartments are separated by the medial and lateral intermuscular septa. Both the anterior and posterior compartments

can be released via a single lateral incision (Figure 4). The adductor compartment is rarely involved

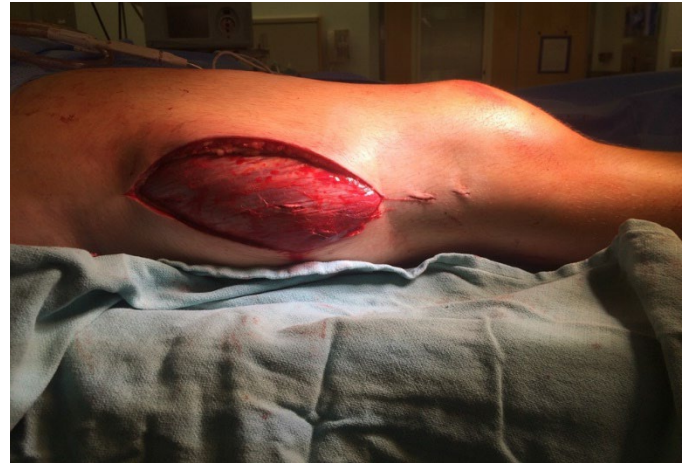
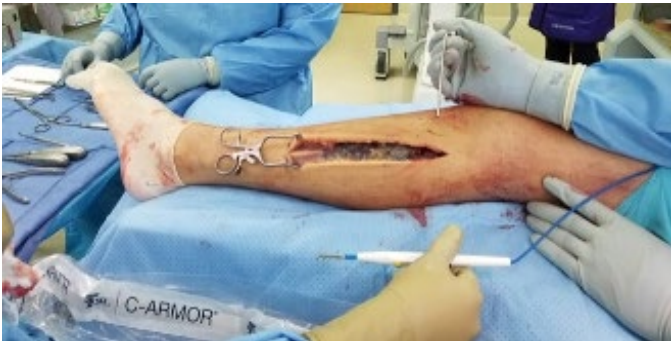
Figure 4. Clinical image of a 15-year-old-male who developed compartment syndrome after sustaining a proximal femur fracture snowboarding (Courtesy of Kenneth Noonan, MD, UW School of Medicine and Public Health, Madison, WI).

Leg

The lower leg contains four compartments: anterior, lateral, superficial posterior, and deep posterior. All four compartments can be released via a dual incision or single incision technique. The dual incision method consists of a posteromedial-based incision for release of the superficial and deep posterior compartments. This incision is 2 cm posterior to the edge of the tibia. The saphenous vein and nerve are retracted anteriorly. The superficial posterior compartment is easily identified and released via skin retraction allowing visualization of the medial gastrocnemius-soleus complex proximally. The deep compartment is more easily identified in the distal third of the leg and often requires retraction of the superficial compartment. The release of the fascia of the deep compartment is confirmed when the posterior tibia is able to be visualized. The anterior and lateral compartments are released via a lateral skin incision. Caution must be exerted distally to identify and protect the superficial peroneal nerve as it exits the fascia of the lateral compartment as it crosses superficial to the anterior compartment.



Figures 5. Incision for single incision fasciotomy (Figures 5-11 courtesy of Chris Souder, MD, Dell Children's Hospital, Austin, TX)

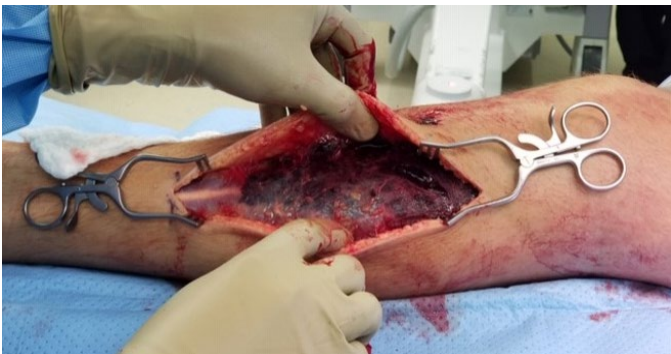

Figure 6. Developing full thickness flaps

A single incision fasciotomy can also be performed by releasing all four compartments through a long lateral incision.³³ The incision begins just distal to the fibular head and is carried posterior to the fibula to a point just proximal to the lateral malleolus (Figure 5). Full thickness anterior and posterior flaps are developed (Figure 6). Palpation of the anterior and lateral intermuscular septa allows identification of the anterior, lateral, and superficial posterior compartments. The superficial peroneal nerve is also identified distally as it exits the lateral compartment fascia and is protected (Figure 7). The fascia overlying the compartments is released, beginning with the superficial posterior compartment before proceeding to the lateral and then anterior compartment (Figure 8). The lateral intermuscular septum is then placed on tension with the use of Allis clamps. The posterior portion of the lateral compartment is bluntly reflected away from the septum until its insertion on the posterolateral fibula is identified (Figure 9). The fascia immediately adjacent to the posterolateral fibula is then

sharply incised from proximal to distal. The release of the deep posterior compartment is confirmed by identification of the flexor hallucis longus muscle which lies posterior to the fibula and is elongated with passive extension of the great toe (Figure 10). The wound is then packed, and delayed closure is performed when edema has resolved (Figure 11).

Foot

The indications for fasciotomy in the foot and the number of compartments that need to be incised within the foot is debated. Most believe that there are four relevant compartments when fasciotomy is considered: medial, lateral, central, and interosseous. Similar to the hand, dorsal incisions over the second and fourth compartments allow releases of the interossei and central compartments. Medial and lateral incisions can allow access for release of the medial and lateral compartments just beneath the first and fifth metatarsals, respectively. Occasionally, in the setting of a calcaneal fracture, a calcaneal compartment release is required via a medial incision.

Wound Management

While emergent fasciotomy is essential in the treatment of acute compartment syndrome, the ensuing open wound(s) generate a new clinical challenge. Extensive soft tissue edema and muscle protrusion (not an actual skin defect) often counteract the goal of primary closure. Viscoelastic properties of skin (stress relaxation and mechanical/biologic creep) can be exploited throughout repeat procedures every 48–72 hours to facilitate delayed primary closure (DPC).³⁴

Closure Techniques

Fasciotomy wound closure techniques contribute to patient outcomes. Wounds are generally reapproximated via delayed primary closure (DPC) or less often by primary closure at the time of fasciotomy. Immediate closure increases the risk of recurrent compartment syndrome and prevents the ability to visualize potentially necrotic muscle.^{35,36,37} When DPC is abandoned by the

treating surgeon, split thickness skin grafting is used for coverage almost exclusively. Skin grafting adds donor-site morbidity, diminishes sensation at the fasciotomy wound site, worsens cosmesis, and may delay mobilization during graft healing.³⁸

Short-term morbidity associated with multiple closure attempts include repetitive general anesthetics, risk of wound infection, persistent soft-tissue insult, prolonged hospitalization, and delayed rehabilitation. Controversial surgeon-dependent decisions include selection of the technique(s) utilized to assist DPC, number of DPC attempts before skin grafting is performed, and whether negative pressure therapy (NPT) should be utilized. Except for routine perioperative antibiotics, there is no consistent recommendation regarding interval antibiotic administration and/or duration during DPC.

Delayed primary closure techniques include conservative options such as gauze, wet-to-dry dressings and temporary synthetic skin dressing such as Epi-GARD, or gradual dermal apposition via dermatotraction. Gradual dermal apposition harnesses the viscoelastic properties of skin and thus, in theory, optimizes (and potentially accelerates) the possibility of DPC. Gradual and uniformly distributed reapproximation of skin edges over time is attempted using variously described methods (sutures or similar materials, static tension devices, or mechanical devices). One very popular technique called the “shoelace technique,” first described by Cohn et al., uses staples along skin edges and that anchor elastic vessel loops that are criss-crossed across the wound which is approximated by tightening the vessel loop knot every 48 hours.³⁸ This technique can be modified to use different materials such as suture and pediatric catheters Interval partial closure at the wound peripheries can be concomitantly performed (Figure 12).

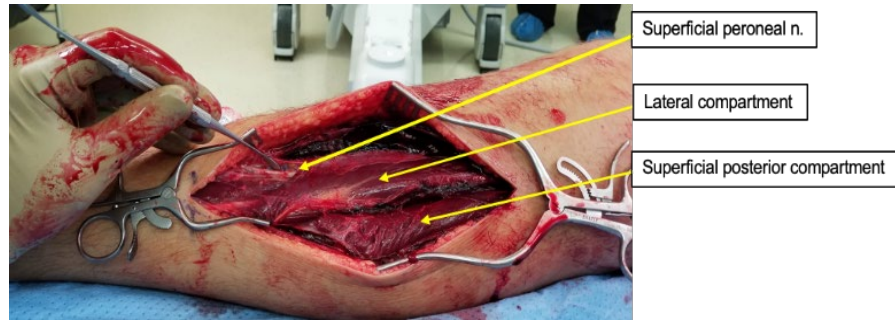


Figure 7. Identification of the superficial peroneal nerve

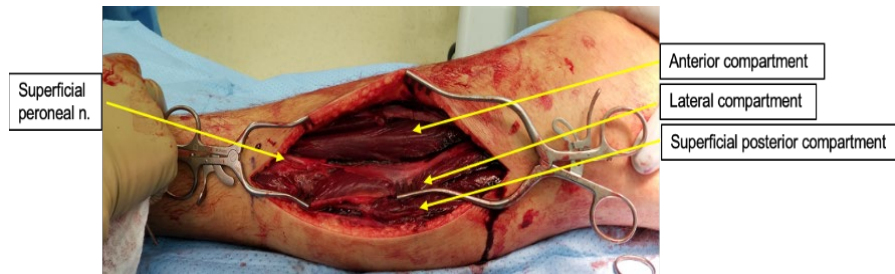


Figure 8. After completion of releases of the anterior, lateral, and superficial posterior compartments

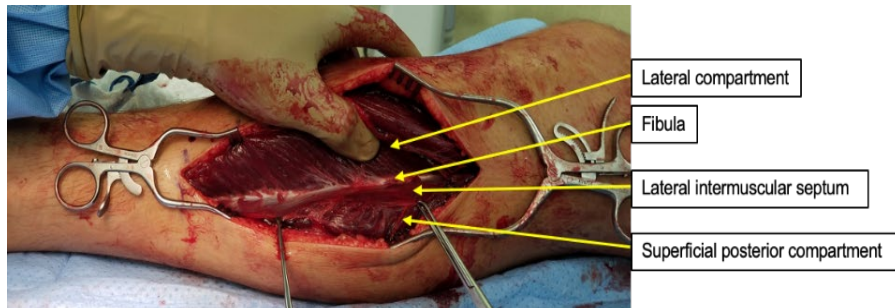


Figure 9. Identification of posterolateral fibula

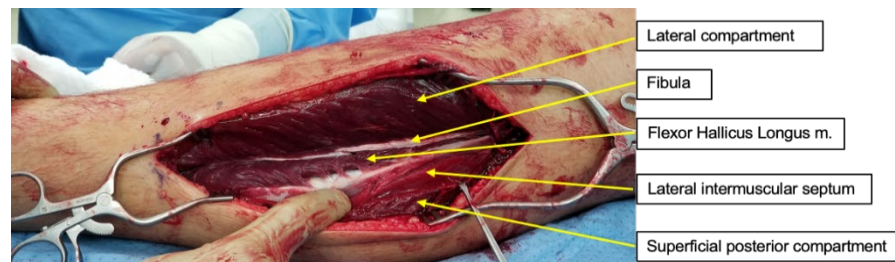


Figure 10. Release of deep posterior compartment. Confirmed with identification of flexor hallucis longus muscle belly

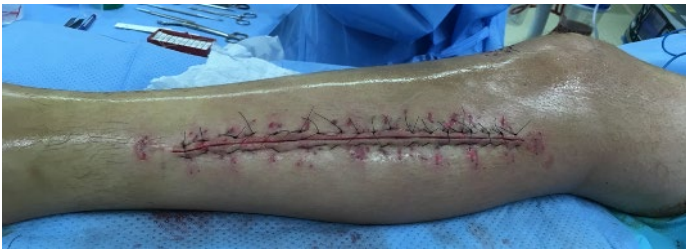

Figure 11. Closure with modified Algower-Donati technique. Of note, the wound was closed in a delayed fashion during the third operative procedure.

A meta-analysis of 22 studies and 332 patients estimated these simple skin reapproximating techniques achieved DPC in 6-20 days, 10.2% required a split-thickness skin graft (STSG), 1.8% experienced minor wound infection, and 0.6% had wound dehiscence.³⁹ Industry dermatotraction products (i.e., DermaClose, Wisebands, etc.) are also available with similar overall outcomes compared to less expensive options. While these specialized products promote bedside adjustment (without a trip to the operating room), many children may not tolerate this, and specialized mechanical devices have not been widely used in children.

Fasciotomy wounds are often initially covered with a vacuum-assisted closure (VAC) device that delivers NPT. This can be performed with or without underlying dermatotraction techniques. Open pore reticulated polyurethane foam covers exposed tissue and allows equally distributed NPT throughout the wound bed while draining unwanted fluid from affected compartments. This creates a physiologic, well-oxygenated, angiogenic environment with decreased bioburden that is ideal for healing.⁴⁰ In contrast, there is concern that wound bed granulation between separated skin margins can increase tissue rigidity (rather than promote elasticity) and hinder DPC. Surgeons should specifically either defer NPT or exercise extreme caution when utilizing NPT over actively bleeding wounds, tenuous vascular repairs, or exposed nerves or arteries.⁴¹

Most authors emphasize that benefits of NPT such as sterility and patient/provider satisfaction (versus open dressings) outweigh the controversial chance that NPT is

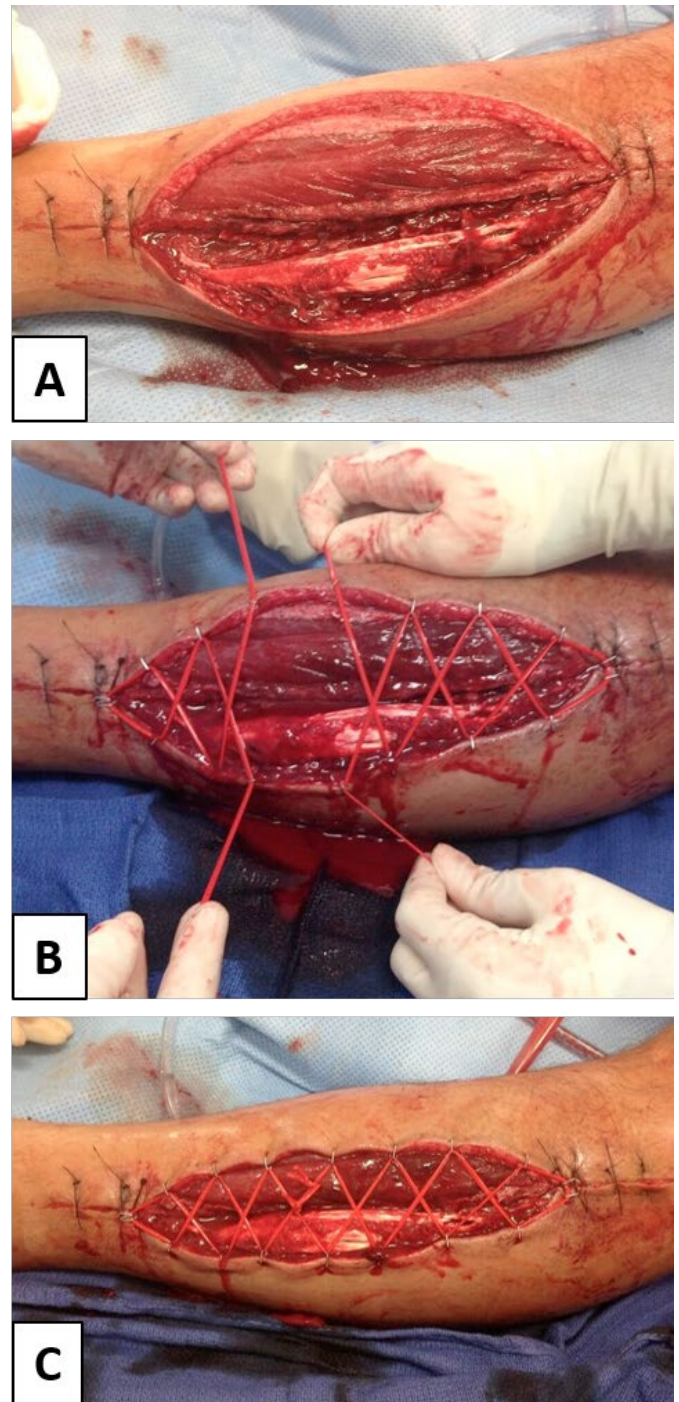


Figure 12. Dermatraction via vessel-loop closure with partial primary closure at the wound peripheries (Courtesy of Dustin A. Greenhill, MD, St. Christopher's Hospital for Children, Philadelphia, PA)

sometimes associated with a higher incidence of STSG. The same meta-analysis in adults that cited a 10.2% rate of STSG after suture approximation techniques reported a 22.8% rate of STSG after NPT.

The combination of vessel-loop dermatotraction with NPT has been described with good results, including one of the larger studies available in the pediatric literature, which is our preferred closure technique for large, swollen fasciotomy wounds^{45,46,47} (Figure 13). The sponge can be placed either deep to or superficial to the dermatotraction device as both techniques have been described. When an incisional VAC technique connects to the open wound, an oil emulsion dressing should be placed between the partially closed skin and the sponge that covers it. Adhesive dressings should not be circumferential.

Pediatric Literature on Fasciotomy Wound Management

Although pediatric studies on fasciotomy wound management are limited, there are some distinct, notable conclusions. Most wounds can be closed via DPC (58-72%), often within three attempts (not counting the index fasciotomy).^{8,47,48} Two large pediatric studies offer divergent advice on how many DPC attempts constitute failure before STSG is performed. Lim et al. retrospectively reviewed 112 pediatric fasciotomy wounds and suggested STSG after the third DPC attempt, given an 81.3% rate of STSG thereafter.¹⁰ However, Rademacher et al. reviewed 82 patients and reported a 94% closure rate during the first DPC attempt and a stable 50-67% closure rate between the second and fifth attempts.⁴⁷ It is unlikely that institutional bias contributed to these differences because both Lim et al. and Rademacher et al. reported some of the highest rates of STSG (32.7% and 23%, respectively) in the pediatric literature. Varying rates of STSG across pediatric studies (roughly 12-32.7%) are likely multifactorial.^{8,10}

Delayed closure techniques described in pediatric studies include gauze dressings, vessel loop dermatotraction,

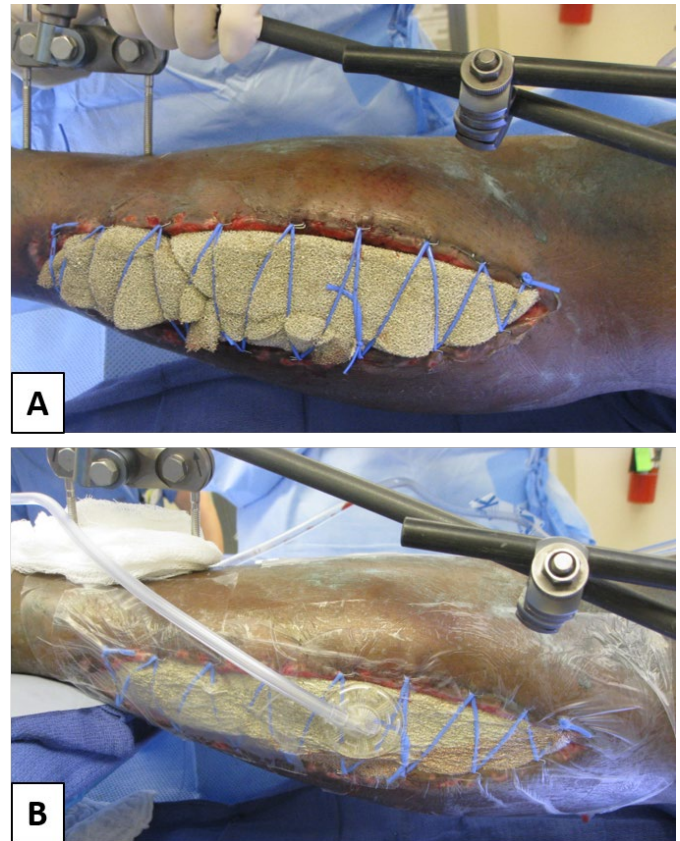


Figure 13. Vessel loop closure combined with VAC therapy. (Courtesy of Dustin A. Greenhill, MD, and Saqib Rehman, MD, MBA, St. Christopher's Hospital for Children, Philadelphia, PA)

NPT, synthetic skin substitute, or a combination of two or more methods. Retrospective comparative cohorts are underpowered and/or too heterogeneous to draw definitive conclusions regarding optimal DPC technique in children (Table 1). For example, Shirley et al. stated vessel loops (which are uniformly beneficial in the adult literature) were “typically used” in both gauze and VAC cohorts but not analyzed separately.⁴⁹ Although the two comparative studies in Table 1 quantitatively suggest VAC therapy delays DPC, Rademacher et al. had similar findings (total procedures, days until final DPC, and overall rates of DPC) among 82 patients closed utilizing vessel loop dermatotraction combined with VAC therapy.^{47,49} Thus, like the adult literature, it is unclear if longer durations of DPC associated with isolated NPT are due to VAC therapy itself or selection bias.

Table 1

		# patients	# procedures	# days to closure
Shirley et al., JCO 2018	Gauze	11	1.9	4.5
	VAC	15	2.6	7.2
	Combination	5	3.4	15.8
Bussell et al., EJTES 2019	Synthetic Skin Replacement (Epigard)	9	1.8	4.9
	VAC	18	3.1	9.4

Lastly, Shirley et al. provided useful information for surgeons regarding cosmesis of fasciotomy wounds in children. Approximately one in four upper extremity patients will not like the appearance of their scar. These concerns were not replicated in the lower extremity. Surprisingly, age, closure by plastic surgery, and STSG were not independent risk factors for cosmetic concerns.⁴⁸

Outcomes After Fasciotomy

Sequelae of missed compartment syndrome have been reported in 0-50% of cases from various series.^{4,34,50} The most feared complications are ischemic contracture, loss of function, nerve deficits, and prolonged pain. In some cases, these symptoms can lead to amputation.⁵¹ Compartment syndrome in the absence of fracture or crush injury is associated with delayed diagnosis and increased muscle necrosis in children and adults.^{5,52}

Even pediatric patients with longer delays in diagnosis and treatment can still have good outcomes.^{4,5,8} The subsequent delayed fasciotomies in this patient population have not shown the same risk of infection that is present in adults.⁴ Extreme delay in diagnosis (> 80 hours) has been associated with poor outcome in one series of lower extremity compartment syndrome, with decreased strength in both patients in that range. Another patient with > 48 hour delay had an excellent outcome.⁴ Broom et al. reported excellent outcomes for decompression up

to 48–72 hours after onset.⁵³ It has been noted that upper extremity compartment syndrome typically has a longer delay to diagnosis.⁶ However, in one series focusing on delay to diagnosis and outcome, a delay was not associated with worsening outcome in the upper extremity.⁶ As a result, it is reasonable to pursue decompression in children despite an apparent delay in diagnosis.^{6,18,53} Once diagnosed, however, pediatric compartment syndrome should be treated with the same sense of urgency that is present for adults.

Atraumatic Compartment Syndrome

Atraumatic compartment syndrome can occur secondary to a variety of causes, and is associated with worse outcomes.^{5,6,51} Earlier intervention (< 6 hours) in this group was associated with improved outcome. Out of 14 upper extremities, poor outcomes included four amputations and three additional limbs with functional deficits.⁵¹ A meta-analysis yielding 165 patients reported full functional recovery in 85% of cases, with incomplete recovery in 15%. This included 10% range of motion deficits, 3% sensory deficits, and 3% weakness. Two percent required amputation.¹⁸

While long-term outcomes appear favorable for adequately treated compartment syndrome, significant short-term morbidity is present with fasciotomies, indicating that an appropriate threshold for treatment must

be maintained. One study focusing on short-term morbidity found an average of two additional surgeries, 6.7% wound infection and 7.7% need for transfusion.⁵⁴ The decision to proceed with fasciotomy should be made carefully.

The risk for “silent” compartment syndrome has been highlighted.⁵⁵ Concerns regarding the effect of PCA analgesia or regional anesthetic techniques on the clinical ability to detect compartment syndrome have generated discussion in both the pediatric and adult literature.^{5,56-58} While publications in the anesthesia literature conclude that there are no convincing evidence that regional anesthesia, epidurals, or PCAs the anesthetic methods contribute to delays in diagnosis, the concern persists among orthopaedic surgeons.^{56,58}

Prophylactic Fasciotomy in Pediatric Orthopaedic Surgery

Tibial osteotomy is of particular concern for compartment syndrome. In one study of 24 children, tibial osteotomy was one of the three most common causes for compartment syndrome.⁵⁹ Previous studies have identified compartment syndrome in up to 20% percent of children after tibial osteotomy.⁶⁰ Some authors have advocated for prophylactic anterior compartment fasciotomy as a result, with no reported cases of subsequent compartment syndrome in their series.⁶¹⁻⁶⁴ A case report has been published which describes a patient who developed compartment syndrome following a tibial osteotomy despite prophylactic anterior compartment fasciotomy and required a return to the OR for formal fasciotomy and dermatomy.⁶⁵ A technique for prophylactic fasciotomy is illustrated in Figure 14.

Tibial tubercle fractures are associated with a relatively high risk of compartment syndrome with reports ranging from 5-20%.^{50,66-68} Fasciotomy at the time of fixation has not specifically been studied, but no long-term effects of the fasciotomies themselves were documented in these series. The role of prophylactic fasciotomy at time of fixation has not been studied, and the majority of cases were specifically noted as present preoperatively.

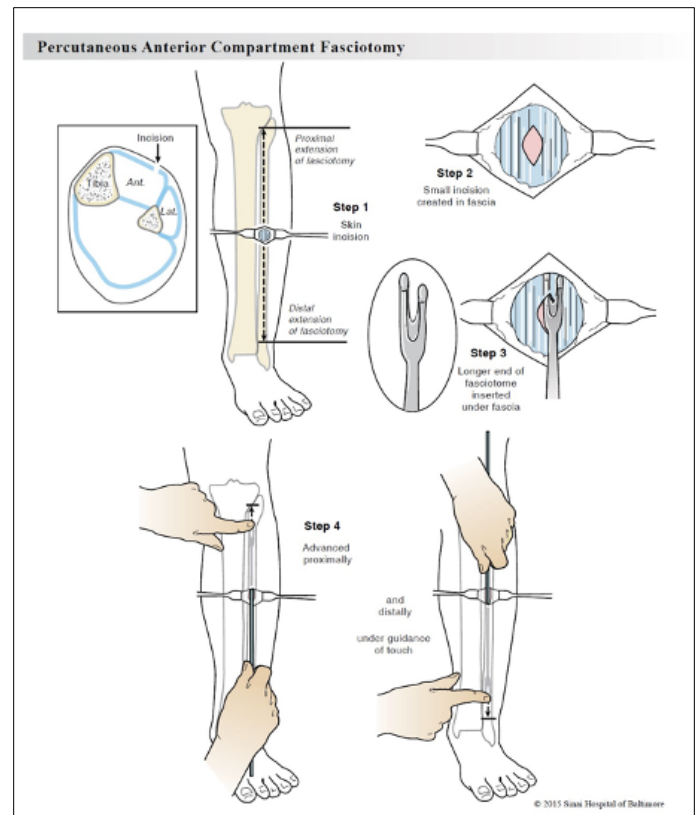


Figure 14. Technique of percutaneous anterior compartment fasciotomy (Courtesy of Sinai Hospital of Baltimore, Baltimore, MD)

Prophylactic fasciotomy may play a role in clinical scenarios where clinical suspicion is present but formal four-compartment fasciotomies are deemed to be excessive. In such a scenario, the surgeon is advised to follow the postoperative exam closely. Leaving a drain in high-risk scenarios may help to decrease the chance of compartment syndrome as it has been shown to reduce sequelae of compartment syndrome after HTO in adults.⁶⁹

Summary

Although pediatric acute compartment syndrome can lead to devastating sequelae, good functional outcomes can occur as a result of prompt diagnosis and treatment. Advances in wound closure techniques including delayed primary closure have allowed for good long-term outcomes after prompt diagnosis and treatment. Delay in diagnosis and treatment remains the best predictor of poor long-term outcomes. Historically, the treatment of acute compartment syndrome in the pediatric population

has followed the principles of management defined for adults. More recent pediatric-specific literature has allowed treatment to be tailored more specifically to the pediatric population.

Additional Links

- *PACS: Pediatric Acute Compartment Syndrome*
http://www.posnacademy.org/media/Pediatric+Acute+Compartment+Syndrome/0_u3v8mu2p/19138922
- *Acute Compartment Syndrome of the Extremity*
https://www.aaos.org/videos/video-detail-page/18271_Videos

References

1. Willy C, et al. Richard von Volkmann Surgeon and Renaissance man. *Clin Orthop Relat Res* 2008 Feb;466(2):500-506.
2. Matava MJ, Whitesides TE, Seiler JG, Hewan-Lowe K, Hutton WC. Determination of the compartment pressure threshold of muscle ischemia in a canine model. *J Trauma*. 1994;37(1):50-58.
3. Heckman MM, Whitesides TE, Grewe SR, Judd RL, Miller M, Lawrence JH. Histologic determination of the ischemic threshold of muscle in the canine compartment syndrome model. *J Orthop Trauma*. 1993;7(3):199-210.
4. Flynn JM, Bashyal RK, Yeger-McKeever M, Garner MR, Launay F, Sponseller PD. Acute Traumatic Compartment Syndrome of the Leg in Children: Diagnosis and Outcome: *The Journal of Bone and Joint Surgery-American Volume*. 2011;93(10):937-941.
5. Livingston K, Glotzbecker M, Miller PE, Hresko MT, Hedequist D, Shore BJ. Pediatric Nonfracture Acute Compartment Syndrome: A Review of 39 Cases. *J Pediatr Orthop*. 2016;36(7):6.
6. Kanj WW, Gunderson MA, Carrigan RB, Sankar WN. Acute compartment syndrome of the upper extremity in children: diagnosis, management, and outcomes. *J Child Orthop*. 2013;7(3):225-233.
7. Noonan KJ, McCarthy JJ. Compartment Syndromes in the Pediatric Patient. *Journal of Pediatric Orthopaedics*. 2010;30:S96.
8. Bae DS, Kadiyala RK, Waters PM. Acute compartment syndrome in children: contemporary diagnosis, treatment, and outcome. *J Pediatr Orthop*. 2001;21(5):680-688.
9. Lee C, Lightdale-Miric N, Chang E, Kay R. Silent compartment syndrome in children: a report of five cases. *Journal of Pediatric Orthopaedics B*. 2014;23(5):467-471.
10. Whitesides TE, Haney TC, Morimoto K, Harada H. Tissue pressure measurements as a determinant for the need of fasciotomy. *Clin Orthop Relat Res*. 1975;(113):43-51.
11. Livingston KS, Glotzbecker MP, Shore BJ. Pediatric Acute Compartment Syndrome. *J Am Acad Orthop Surg*. 2017;25(5):358-364.
12. Staudt JM, Smeulders MJC, van der Horst CMAM. Normal compartment pressures of the lower leg in children. *The Journal of Bone and Joint Surgery British volume*. 2008;90-B(2):215-219.
13. Tharakan SJ, Subotic U, Kalisch M, Staubli G, Weber DM. Compartment Pressures in Children With Normal and Fractured Forearms: A Preliminary Report. *J Pediatr Orthop*. 2016;36(4):410-415.
14. Royle SG. The role of tissue pressure recording in forearm fractures in children. *Injury*. 1992;23(8):549-552. doi:10.1016/0020-1383(92)90158-o
15. Shuler MS, Roskosky M, Kinsey T, et al. Continual near-infrared spectroscopy monitoring in the injured lower limb and acute compartment syndrome: an FDA-IDE trial. *Bone Joint J*. 2018;100-B(6):787-797.
16. Shuler MS, Reisman WM, Whitesides TE, et al. Near-infrared spectroscopy in lower extremity trauma. *J Bone Joint Surg Am*. 2009;91(6):1360-1368.
17. Cole AL, Herman RA, Heimlich JB, Ahsan S, Freedman BA, Shuler MS. Ability of near infrared spectroscopy to measure oxygenation in isolated upper extremity muscle compartments. *J Hand Surg Am*. 2012;37(2):297-302.
18. Lin JS, Samora JB. Pediatric acute compartment syndrome: a systematic review and meta-analysis. *Journal of Pediatric Orthopaedics B*. 2020;29(1):90-96.
19. Sees JA, Cutler GJ, Ortega HW. Risk Factors for Compartment Syndrome in Pediatric Trauma Patients. *Pediatric Emergency Care*. 2018;Publish Ahead of Print.
20. Shore BJ, Glotzbecker MP, Zurakowski D, Gelbard E, Hedequist DJ, Matheney TH. Acute Compartment Syndrome in Children and Teenagers With Tibial Shaft Fractures: Incidence and Multivariable Risk Factors. *J Orthop Trauma*. 2013;27(11):6.

21. Ferlic PW, Singer G, Kraus T, Eberl R. The acute compartment syndrome following fractures of the lower leg in children. *Injury*. 2012;43(10):1743-1746.
22. Blakemore LC, Cooperman DR, Thompson GH, Wathey C, Ballock RT. Compartment syndrome in ipsilateral humerus and forearm fractures in children. *Clin Orthop Relat Res*. 2000;(376):32-38.
23. Baghdadi S. Pediatric Floating Elbow Injuries Are Not as Problematic as They Were Once Thought to Be: A Systematic Review. *Journal of Pediatric Orthopaedics*. 2020;40(8):380-386.
24. Muchow RD, Riccio AI, Garg S, Ho CA, Wimberly RL. Neurological and Vascular Injury Associated With Supracondylar Humerus Fractures and Ipsilateral Forearm Fractures in Children. *Journal of Pediatric Orthopaedics*. 2015;35(2):121-125.
25. Yuan P, Pring M, Gaynor T, Mubarak S, Newton P. Compartment Syndrome Following Intramedullary Fixation of Pediatric Forearm Fractures. *Journal of Pediatric Orthopaedics*. 2004;24(4):370-375.
26. Blackman AJ, Wall LB, Keeler KA, et al. Acute Compartment Syndrome After Intramedullary Nailing of Isolated Radius and Ulna Fractures in Children: *Journal of Pediatric Orthopaedics*. 2014;34(1):50-54.
27. Flynn JM, Jones KJ, Garner MR, Goebel J. Eleven Years Experience in the Operative Management of Pediatric Forearm Fractures. *Journal of Pediatric Orthopaedics*. 2010;30(4):313-319.
28. Pandya NK, Edmonds EW, Mubarak SJ. The incidence of compartment syndrome after flexible nailing of pediatric tibial shaft fractures. *J Child Orthop*. 2011;5(6):439-447.
29. Challa ST, Hargens AR, Uzosike A, Macias BR. Muscle Microvascular Blood Flow, Oxygenation, pH, and Perfusion Pressure Decrease in Simulated Acute Compartment Syndrome. *J Bone Joint Surg Am*. 2017 Sep 6;99(17):1453-1459.
30. Mars M, Hadley GP. Raised intracompartmental pressure and compartment syndromes. *Injury*. 1998 Jul;29(6):403-11.
31. Erdős J, Dlaska C, Szatmary P, Humenberger M, Vécsei V, Hajdu S. Acute compartment syndrome in children: a case series in 24 patients and review of the literature. *Int Orthop*. 2011;35(4):569-575.
32. Erdős J, Dlaska C, Szatmary P, Humenberger M, Vécsei V, Hajdu S. Acute compartment syndrome in children: a case series in 24 patients and review of the literature. *Int Orthop*. 2011;35(4):569-575.
33. Maheshwari R, Taitsman LA, Barei DP. Single-incision fasciotomy for compartmental syndrome of the leg in patients with diaphyseal tibial fractures. *J Orthop Trauma*. 2008 Nov-Dec;22(10):723-30.
34. Wilhelmi BJ, Blackwell SJ, Mancoll JS, Phillips LG. Creep vs. stretch: a review of the viscoelastic properties of skin. *Ann Plast Surg*. 1998;41:215-219.
35. Hussmann J, Kucan JO, Zamboni WA. Elevated compartmental pressures after closure of a forearm burn wound with a skin stretching device. *Burns* 1997; 23:154-6.
36. Saffle JR, Zeluff GR, Warden GD. Intramuscular pressure in the burned arm: measurement and response to escharotomy. *Am J Surg* 1980;140:825-30.
37. Mubarak SJ, Hargens AR. Acute compartment syndromes. *Surg Clin North Am* 1983;63:539-65.
38. Cohn BT, Shall J, Berkowitz M. Forearm fasciotomy for acute compartment syndrome; a new technique of delayed primary closure. *Orthopedics*. 1986;9:1243-1246.
39. Kakagia D. How to Close a Limb Fasciotomy Wound: An Overview of Current Techniques. *Int J Low Extrem Wounds*. 2015 Sep;14(3):268-76.
40. Erba P, Ogawa R, Ackermann M, Adini A, Miele LF, Dastouri P, Helm D, Mentzer SJ, D'Amato RJ, Murphy GF, Konerding MA, Orgill DP. Angiogenesis in wounds treated by microdeformational wound therapy. *Ann Surg*. 2011 Feb;253(2):402-9.
41. White RA, Miki RA, Kazmier P, Anglen JO. Vacuum-assisted closure complicated by erosion and hemorrhage of the anterior tibial artery. *J Orthop Trauma*. 2005 Jan;19(1):56-9.
42. Matt SE, Johnson LS, Shupp JW, Kheirbek T, Sava JA. Management of fasciotomy wounds--does the dressing matter? *Am Surg*. 2011 Dec;77(12):1656-60.
43. Zannis J, Angobaldo J, Marks M, DeFranzo A, David L, Molnar J, Argenta L. Comparison of fasciotomy wound closures using traditional dressing changes and the vacuum-assisted closure device. *Ann Plast Surg*. 2009 Apr;62(4):407-9.
44. Kakagia D, Karadimas EJ, Drosos G, Ververidis A, Trypsiannis G, Verettas D. Wound closure of leg fasciotomy: comparison of vacuum-assisted closure versus shoelace technique. A randomised study. *Injury*. 2014 May;45(5):890-3.

45. Moran SG, Windham ST, Cross JM, Melton SM, Rue LW 3rd. Vacuum-assisted complex wound closure with elastic vessel loop augmentation: a novel technique. *J Wound Care*. 2003 Jun;12(6):212-3.
46. Eceviz E, Çevik HB. Shoelace Technique Plus Negative-Pressure Wound Therapy Closure in Fasciotomy Wounds. *Adv Skin Wound Care*. 2020 Sep;33(9):497-500.
47. Rademacher E, Miller PE, Jordan E, May CJ, Glotzbecker MP, Bae DS, Hedequist DJ, Shore BJ. Management of Fasciotomy Incisions After Acute Compartment Syndrome: Is Delayed Primary Closure More Feasible in Children Compared With Adults? *J Pediatr Orthop*. 2020 Apr;40(4):e300-e305.
48. Shirley ED, Mai V, Neal KM, Kiebzak GM. Wound closure expectations after fasciotomy for paediatric compartment syndrome. *J Child Orthop*. 2018 Feb 1;12(1):9-14.
49. Bussell HR, Aufdenblatten CA, Gruenenfelder C, Altermatt S, Tharakan SJ. Comparison of lower extremity fasciotomy wound closure techniques in children: vacuum-assisted closure device versus temporary synthetic skin replacement. *Eur J Trauma Emerg Surg*. 2019 Oct;45(5):809-814.
50. Frey S, Hosalkar H, Cameron DB, Heath A, David Horn B, Ganley TJ. Tibial tuberosity fractures in adolescents. *J Child Orthop*. 2008;2(6):469-474.
51. Prasarn ML, Ouellette EA, Livingstone A, Giuffrida AY. Acute Pediatric Upper Extremity Compartment Syndrome in the Absence of Fracture. *J Pediatr Orthop*. 2009;29(3):6.
52. Hope MJ, Ed M, McQueen MM, Ed(Orth) F. Acute Compartment Syndrome in the Absence of Fracture: *Journal of Orthopaedic Trauma*. 2004;18(4):220-224.
53. Broom A, Schur MD, Arkader A, Flynn J, Gornitzky A, Choi PD. Compartment syndrome in infants and toddlers. *J Child Orthop*. 2016;10(5):453-460.
54. Lim KBL, Laine T, Chooi JY, Lye WK, Lee BJY, Narayanan UG. Early morbidity associated with fasciotomies for acute compartment syndrome in children. *J Child Orthop*. 2018;12(5):480-487.
55. Frei B, Sommer-Joergensen V, Holland-Cunz S, Mayr J. Acute compartment syndrome in children; beware of “silent” compartment syndrome. *Medicine (Baltimore)*. 2020;99(23).
56. Mar GJ, Barrington MJ, McGuirk BR. Acute compartment syndrome of the lower limb and the effect of postoperative analgesia on diagnosis. *Br J Anaesth*. 2009;102(1):3-11.
57. Price C, Ribeiro J, Kinnebrew T. Compartment syndromes associated with postoperative epidural analgesia. A case report. *J Bone Joint Surg Am*. 1996 Apr;78(4):597-9.
58. Cometa MA, Esch AT, Boezaart AP. Did continuous femoral and sciatic nerve block obscure the diagnosis or delay the treatment of acute lower leg compartment syndrome? A case report. *Pain Med*. 2011;12(5):823-828.
59. Matsen FAI, Veith RG. Compartmental Syndromes in Children. *Journal of Pediatric Orthopaedics* 1981. 1981;1(1):33-41.
60. Steel HH, Sandrow RE, Sullivan PD. Complications of tibial osteotomy in children for genu varum or valgum. Evidence that neurological changes are due to ischemia. *J Bone Joint Surg Am*. 1971;53(8):1629-1635.
61. Matsen FA, staheli LT. Neurovascular complications following tibial osteotomy in children. A case report. *Clin Orthop Relat Res*. 1975;(110):210-214.
62. Rab GT. Oblique tibial osteotomy revisited. *J Child Orthop*. 2010;4(2):169-172.
63. Pinkowski JL, Weiner DS. Complications in proximal tibial osteotomies in children with presentation of technique. *J Pediatr Orthop*. 1995;15(3):307-312.
64. Walton DM, Liu RW, Farrow LD, Thompson GH. Proximal tibial derotation osteotomy for torsion of the tibia: a review of 43 cases. *J Child Orthop*. 2012;6(1):81-85.
65. Mueller KL, Farley FA. Superficial and deep posterior compartment syndrome following high tibial osteotomy for tibia vara in a child. *Orthopedics*. 2003;26(5):513-514.
66. Pandya NK, Edmonds EW, Mubarak SJ. Tibial Tubercle Fractures: Complications, Classification, and the Need for Intra-articular Assessment. *J Pediatr Orthop*. 2012;32(8):11.
67. Polakoff DR, Bucholz RW, Ogden JA. Tension band wiring of displaced tibial tuberosity fractures in adolescents. *Clin Orthop Relat Res*. 1986;(209):161-165.
68. Wiss DA, Schilz JL, Zionts L. Type III fractures of the tibial tubercle in adolescents. *J Orthop Trauma*. 1991;5(4):475-479.
69. Gibson MJ, Barnes MR, Allen MJ, Chan RN. Weakness of foot dorsiflexion and changes in compartment pressures after tibial osteotomy. *J Bone Joint Surg Br*. 1986;68(3):471-475.