

# Jump Gait in Spastic Diplegia: Patient Outcome

M. Wade Shrader, MD

Nemours A.I. duPont Hospital for Children, Wilmington, DE

## Treatment

Based on the history, physical exam, and the gait analysis, it was decided to perform a psoas lengthening over the pelvic brim, a medial and lateral hamstring lengthening, and a gastrocnemius recession. Postoperatively, she was mobilized weight bearing as tolerated in a short leg cast, knee immobilizers on and off every 2 hours, and 4 hours of prone time each day for 6 weeks. After that, she was placed in solid ankle-foot orthosis. *See attached postoperative video.*

She returned for a postoperative gait analysis 12 months later. Figure 8 shows increased GDI compared to pre-operative values. Pelvic kinematics show a slightly increased pelvic tilt, but hip kinematics also showed slight improvements in internal rotation (Figure 9 and 10). Knee and ankle kinematics show marked improvements in knee extension and ankle dorsiflexion (Figures 11 and 12), and the pedobarograph shows improved total foot contacts (Figure 13).

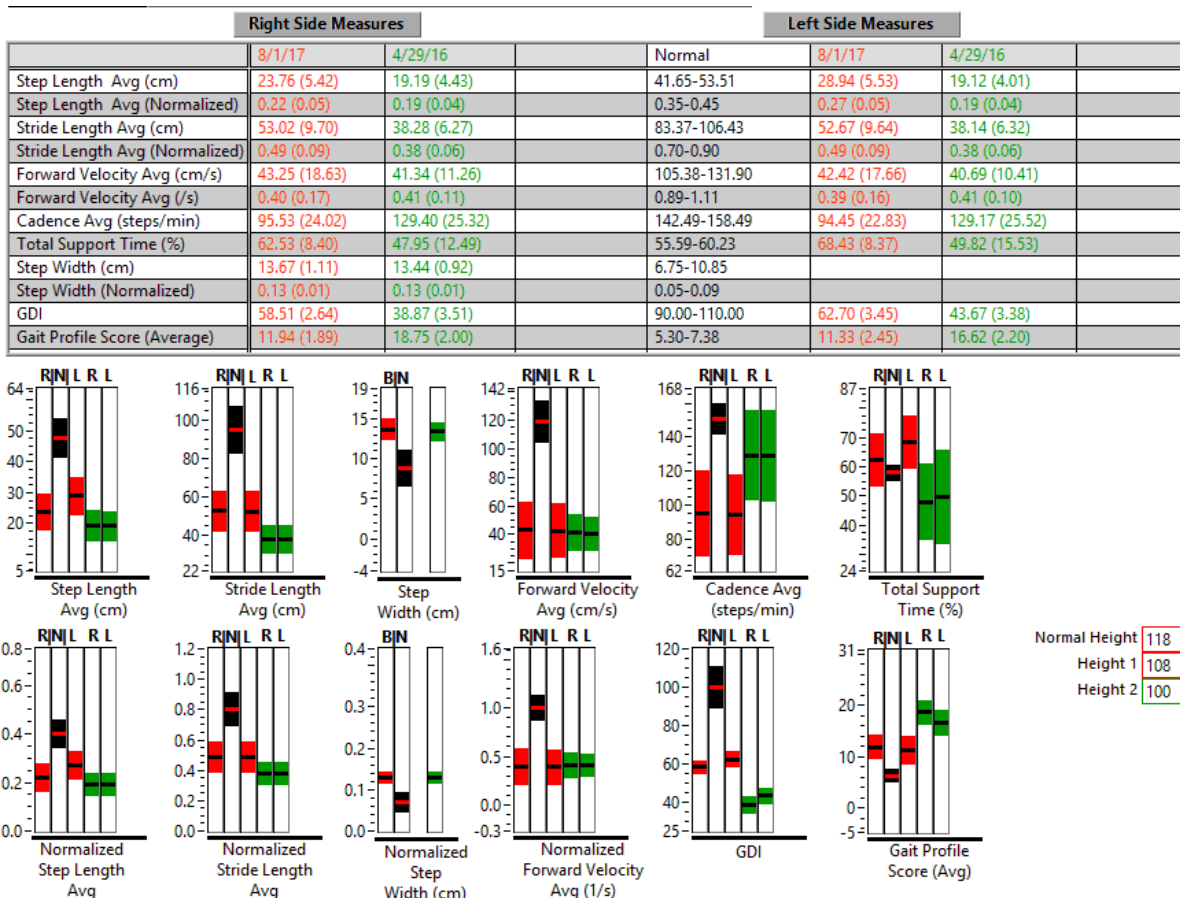


Figure 8. Postoperative Temporodistance Parameters

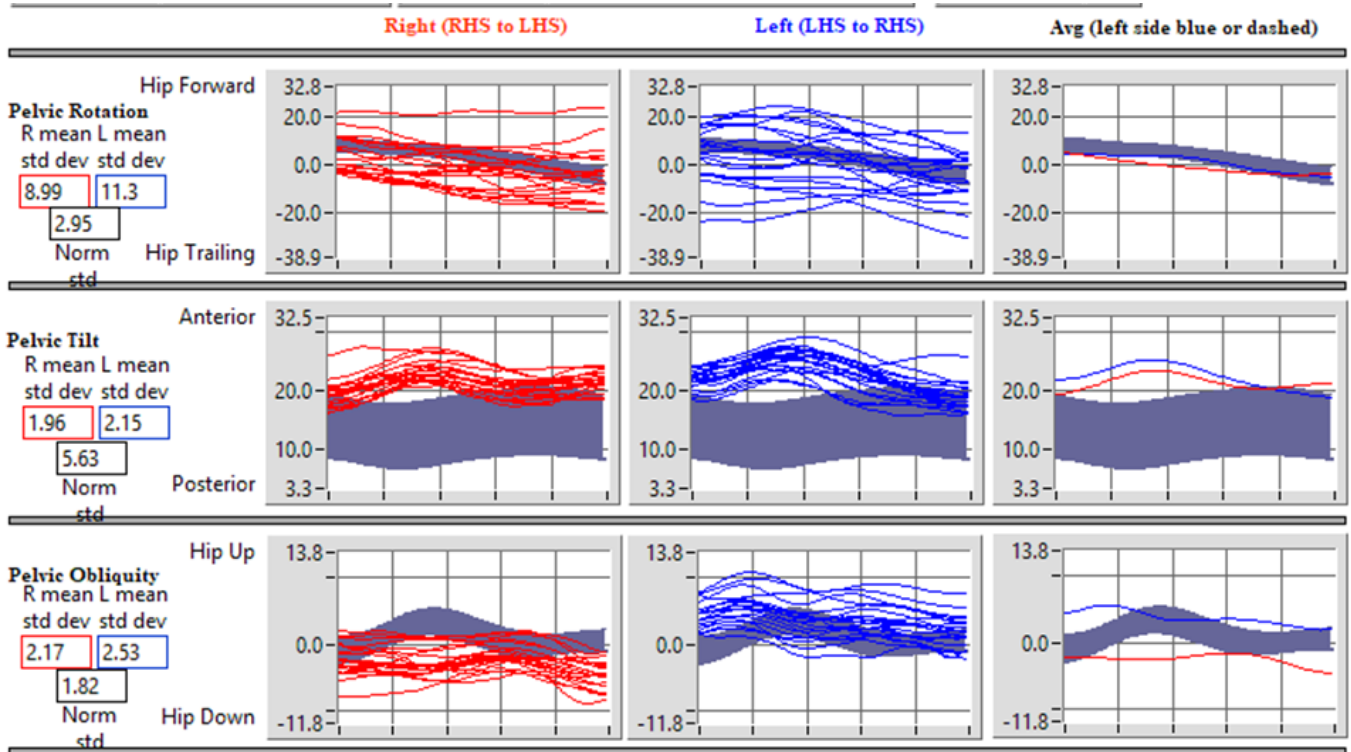


Figure 9. Postoperative Pelvic Kinematics

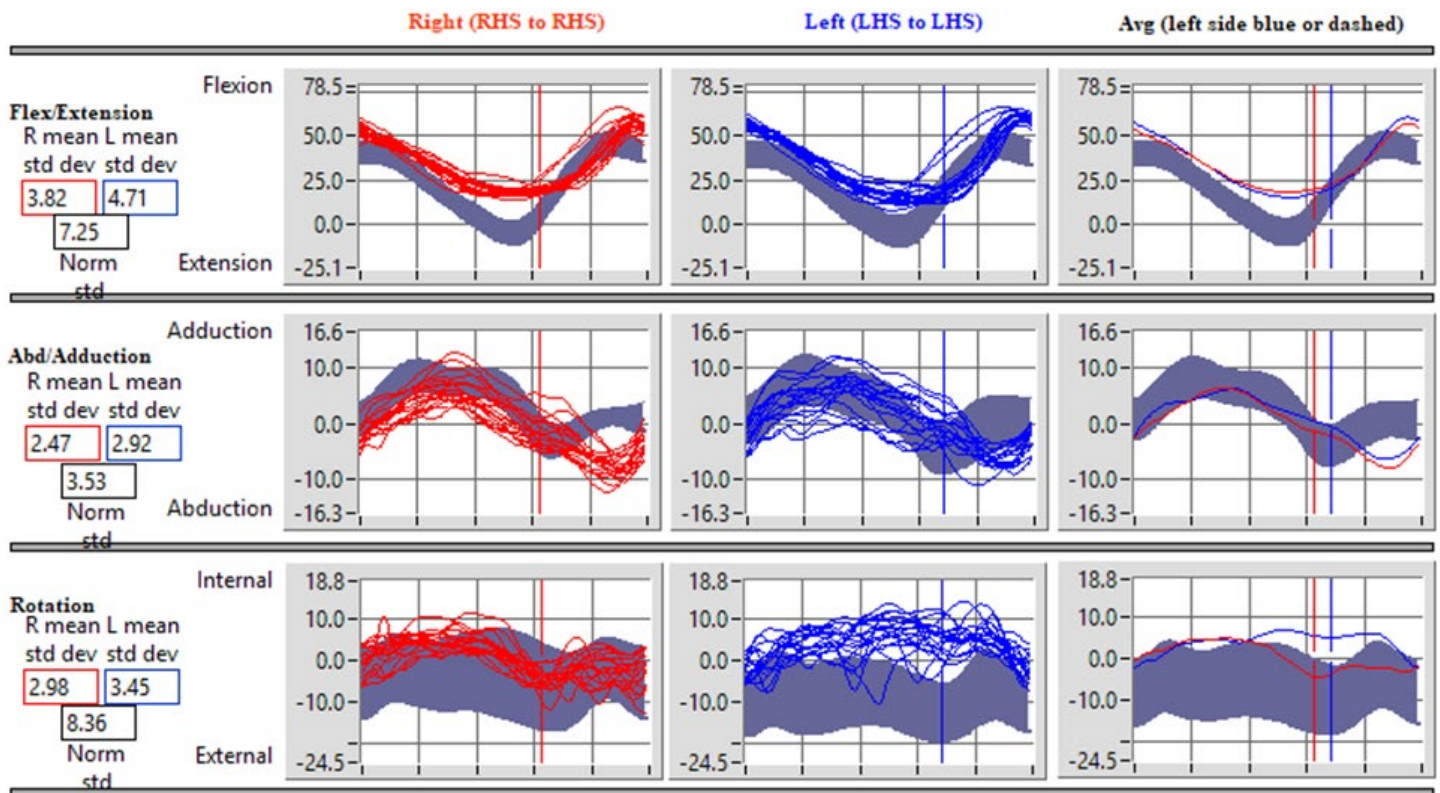


Figure 10. Postoperative Hip Kinematics

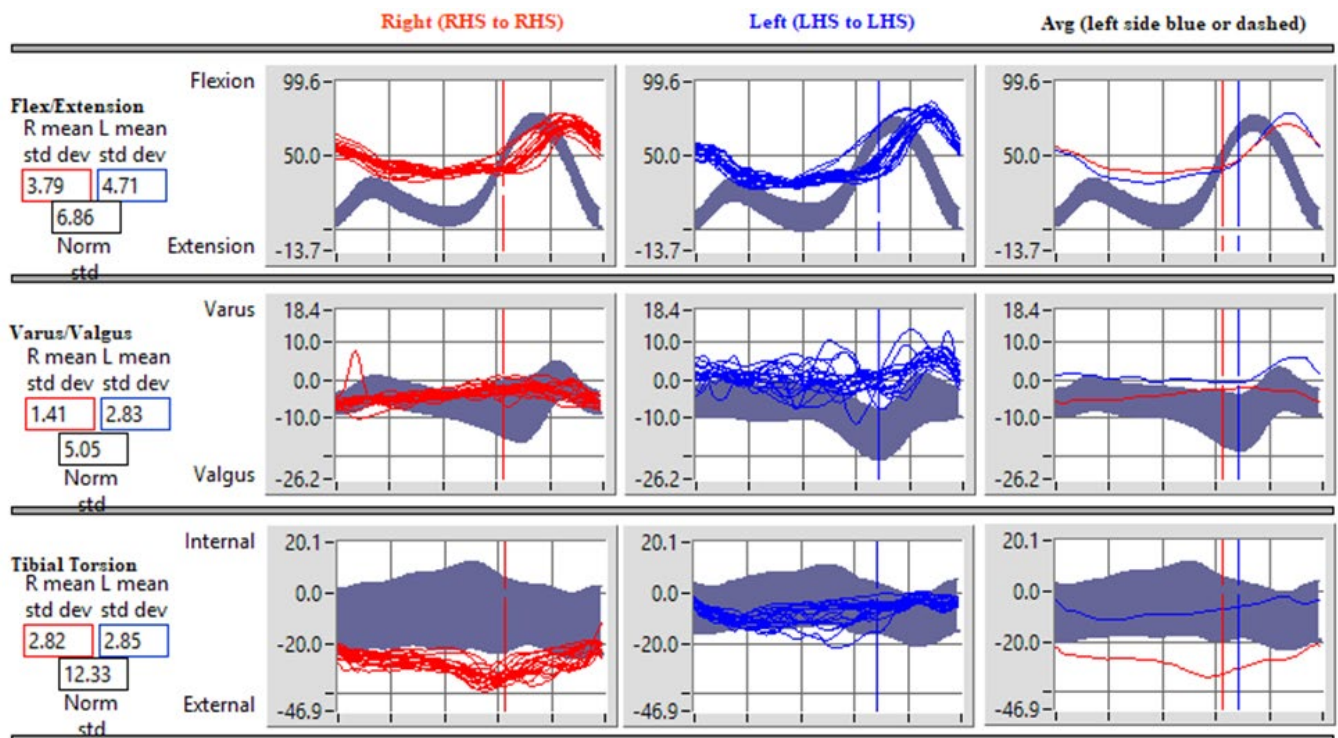


Figure 11. Postoperative Knee Kinematics

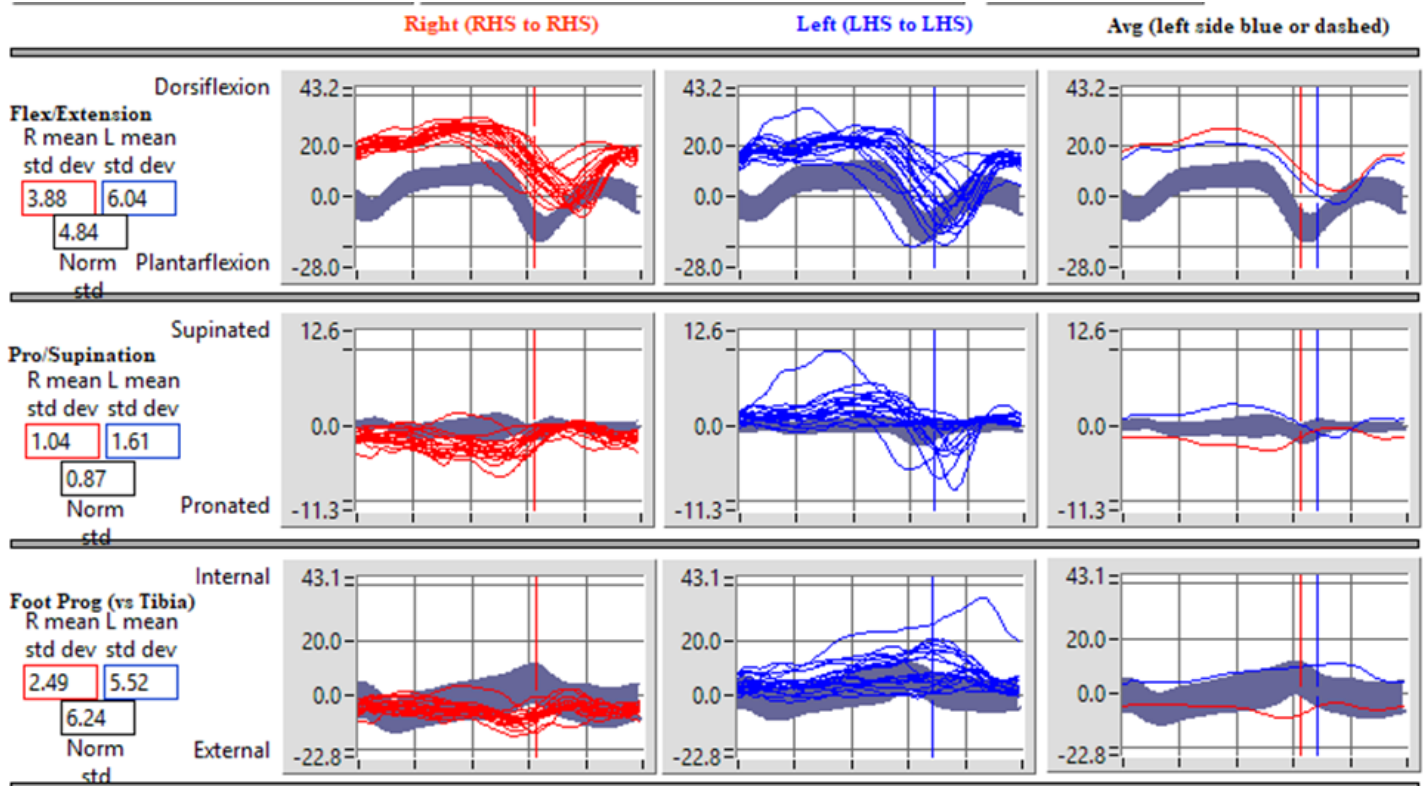


Figure 12. Postoperative Ankle Kinematics

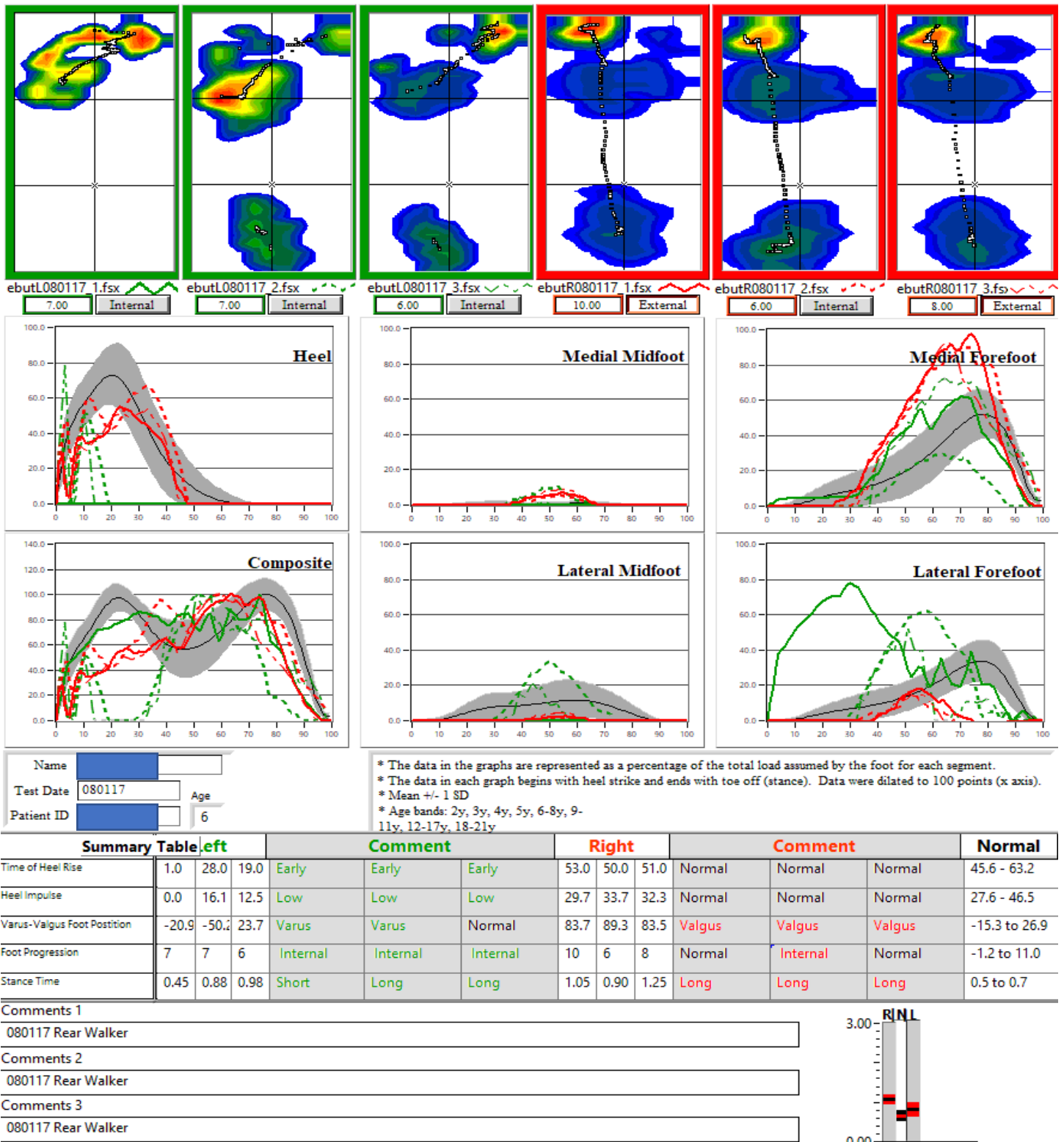


Figure 13. Postoperative Pedobarograph