

# Placement of Hexapod External Fixator for Deformity Correction

Christopher Iobst, MD, FAOA

The Ohio State University, College of Medicine; Nationwide Children's Hospital, Columbus, OH

## Abstract:

Hexapod circular external fixators provide a powerful technique for correcting limb deformity. The ability to correct multi-planar deformity sequentially or simultaneous in a gradual manner is unique to this method. This article provides a review of the pertinent preoperative, intraoperative and postoperative details that will help the surgeon achieve a successful outcome with hexapod circular external fixators.

## Key Concepts:

- Patient selection criteria for hexapod circular external fixation
- Steps to preoperative planning for hexapod circular external fixation cases
- Intraoperative pearls to have a smooth, successful surgical experience when applying a hexapod circular external fixator
- Postoperative management tips for patients with hexapod circular external fixators

## Introduction

Hexapod circular external fixators can be utilized on any long bone or joint deformity. However, certain anatomic locations, such as below the knee, are better tolerated by patients. Multiplanar tibial deformity is the ideal indication for a hexapod circular external fixator. With proper planning, four-dimensional deformities (angulation, translation, rotation, length) can be sequentially or simultaneously corrected using this technique. The pertinent details and decision making required to select the proper patient, analyze the deformity, and apply the hexapod circular external fixator to the tibia are discussed in this article.

## Patient Selection

Because even in the best circumstances limb reconstruction with an external fixator will require a several month journey for the patient and the healthcare team, proper patient selection prior to surgery is important. Prior to considering managing any patient with a hexapod external fixator the following criteria should be evaluated:

- 1) Does the patient have a strong support system?
- 2) Will the patient be able to comply with the postoperative physical therapy and weight-bearing recommendations?
- 3) Does the patient have adequate transportation to attend the required multiple office visits?
- 4) Does the patient have the ability to perform accurate strut adjustments?

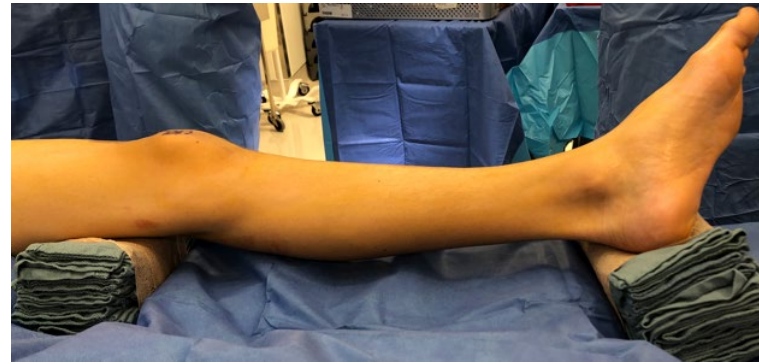If the patient does not meet these criteria preoperatively a hexapod external fixator may not be the best choice of management. In addition, patients with a previous history of depression, anxiety, or chronic pain are at risk for a difficult postoperative course and may benefit from a rigorous behavioral health evaluation prior to surgery.

## Deformity Analysis and Preoperative Planning

A thorough deformity analysis of the patient's clinical and radiographic anatomy is necessary. Clinically, an assessment of the following examination points are recommended: a) Knee and ankle joint range of motion; b) Knee ligamentous stability; c) Neurovascular function of the limb; d) Prone evaluation of limb rotation (especially thigh-foot angle); e) Measurement of the leg circumference for ring sizing. The proper ring size should have one to two fingerbreadths between the ring and the skin circumferentially.

A complete deformity analysis using the malalignment test should be performed on the lower extremity.<sup>1</sup> This involves obtaining a full length standing anteroposterior bilateral lower extremity radiograph as well as dedicated standing anteroposterior and lateral views of the tibia. Standard measurement of the mechanical axis and the accompanying coronal and sagittal plane joint orientation angles should be performed to find the apex (apices) of the deformity. Once the four-dimensional analysis is complete (angulation, rotation, length, and translation), this information can be transferred to the hexapod external fixator computer software to begin the process of planning the surgery and building the frame. Prebuilding of the hexapod frame will save time in the operating room and simplifies the frame attachment process by having a frame that already matches the limb deformity. Manipulation of the software to adjust the distance between the rings can be performed preoperatively to minimize the number of postoperative strut changes required.

Other preoperative decisions include the number of rings to be used to build a stable frame construct and the num-



**Figure 1.** Proper positioning makes the frame application easier. Place a bump under the hip to hold the patella in a directly anterior position. Bumps under the thigh and ankle will allow the external fixator to be manipulated on the limb without obstruction from the operating room table.

ber and the location of the pins and wires to be used on each ring. To increase stability, the fixation elements should be spread over the length of each bone segment and inserted in multiple planes. This pattern will provide the maximal frame stability which increases the patient's comfort to participate in physical therapy and promotes earlier weight bearing. The final consideration is the diameter of the half pins to be used. Since the half pin stiffness is proportional to  $r^4$ , increasing the diameter of the half pin even by one millimeter will vastly increase the overall frame stability.<sup>2</sup> As a general rule, the drill hole for the half pin should not be  $> 1/3$  the diameter of the bone to avoid creating a stress riser when the pin is removed.

## Intraoperative Concerns Prior to Starting Surgery

Prior to making an incision, the following steps should be performed to optimize the surgical performance. The patient should be positioned supine on a radiolucent table with the patella facing directly anterior. A bump under the hip may be necessary to achieve this position. For better visualization, the entire limb should be prepped and draped not just the segment below the knee. Towel bumps should be constructed and placed behind the distal femur and heel. This allows the limb to be elevated off of the table so the fixator can hang freely (Figure 1).

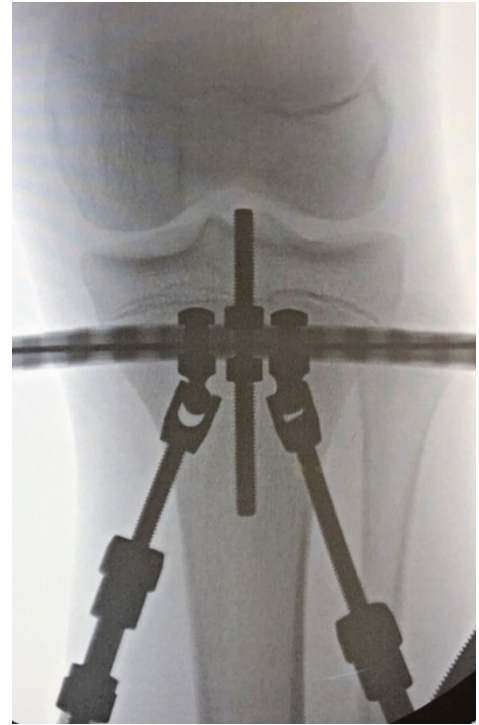Prior to surgery, have a conversation about the surgical plan with the entire operating room team. The anesthesia staff should be reminded not to paralyze the patient. Flickering of the toes is an indication that the placement of a transfixion wire is passing too close to a nerve. Neuromuscular blockade of the patient prevents the appearance of this warning sign. The desired choice of antibiotic and any potential need for regional anesthesia should also be discussed with the anesthesia team prior to surgery.

Review the steps of the surgery with the surgical technician assigned to the case. These cases typically require a lot of equipment and trays. The sheer volume of instruments needed can be overwhelming to a technician that is not familiar with external fixation. A quick explanation of the planned surgery can help to orient the technician and make the case flow more efficiently. Since the diameter of the half pins and the number of pin/wire elements have been determined preoperatively, the technician can have the fixation elements for each pin/wire prepared and placed on the Mayo stand for you. The correct drill bit size should be opened and ready for use before the case. Each case should have a new, sharp drill bit.

## Surgical Steps

If a fibular osteotomy is to be performed, it is generally easier to do it first, before application of the external fixator. Drilling multiple holes with an Ilizarov wire prior to using an osteotome helps to make the fibular osteotomy process easier and more reliable.

Ring placement depends on the surgeon's preferred method. If the frame has been prebuilt, slide the frame onto the limb and verify that the ring sizes are correct. Determine if each ring is orthogonal to its respective bone segment as planned and make any strut adjustments as necessary. If the surgeon prefers the rings first method, slide each individual ring onto the patient and determine the correct ring size. If a full ring is going to be used proximally, make sure this ring is already in place on the limb before beginning to attach the distal ring(s).



**Figure 2.** Intraoperative radiograph demonstrating placement of the initial reference wire to the proximal ring. This is the most important step in the external fixator application process. Spend extra time to ensure the alignment is perfect. A temporary threaded rod inserted in the center hole can be used as a visual guide to help determine the ring alignment.

Fixation elements can be placed in a variety of patterns and there is no right or wrong order to do it as long as you follow the principles: use meticulous surgical technique to avoid thermal necrosis of the bone or skin tension when placing each pin or wire, attach multiple pins or wires to each ring, spread the fixation out over the length of the bone segment, and place the pins/wires in multiple planes.

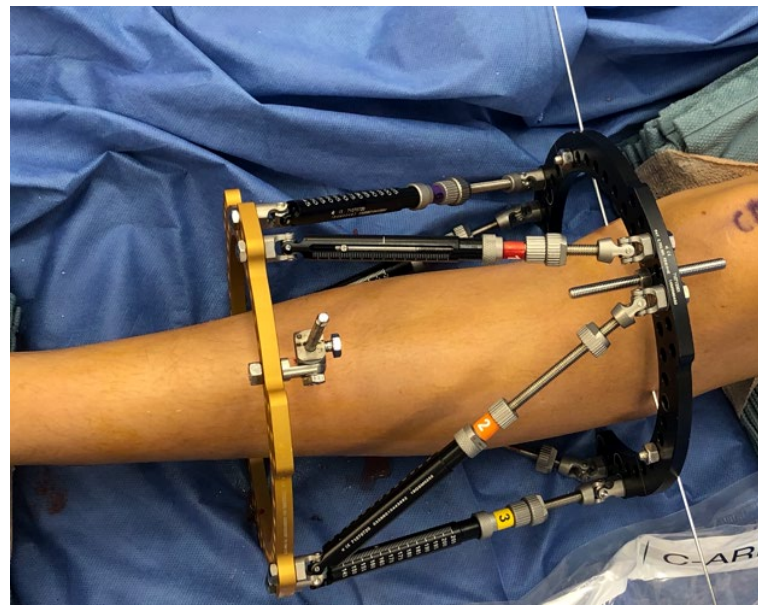
The author's preferred pattern involves first placing a transverse reference wire from lateral to medial just below the physis (or physeal scar) orthogonal to the proximal bone segment. Slide the proximal ring medial or lateral along the wire until the center of the ring is over the center of the bone segment. A short, threaded rod attached to the anterior center hole of the ring will provide a visual guide for centering the ring and is helpful for

determining if it is in line with the mechanical axis of the bone segment. When mounting the ring, also pay attention that the ring is not internally or externally rotated relative to the anterior tibia. The center tab of the ring should be located directly anterior unless the surgeon decides to rotate the ring on purpose. Mounting the proximal ring on the reference wire is the key element of the surgery. Spend extra time to make sure this wire placement and frame mounting is perfect (Figure 2). Since the wire will be attached directly to the ring, it can be fully tensioned to 130 kg. If you are concerned about using transfixion wires in your patient, you can replace this wire with a half pin at the end of the case.

The second fixation element is a half pin placed in an anterior to posterior direction attached to the distal ring of a two-ring construct or the middle ring of a three-ring construct. This pin should be placed using a fixation element that allows some angular variability so the frame can be rotated around the wire until it is orthogonal in both the coronal and sagittal planes (Figure 3). Once the frame position is locked by the wire on the proximal ring and the half pin on the middle/distal ring, the rest of the procedure is designed to add additional fixation elements to each ring to create a stable frame construct.

The initial half pin (and each ensuing half pin) should be inserted by hand. You can feel when the pin engages the far cortex because it should get harder to turn. As soon as the far cortex is encountered, just advance the pin three to five more millimeters to achieve full bicortical purchase without over inserting the pin. With practice, it is not necessary to check each pin with fluoroscopy since you can feel when the pin is properly inserted.

If a distal ring block is utilized (three-ring frame), make sure the distal ring has appropriate circumferential clearance after it is attached to the middle ring. Be sure that the distal ring does not limit ankle dorsiflexion. There should be at least two fixation elements attached to each ring of the distal ring block for a total of four elements in the long distal segment. A straight medial to lateral half



**Figure 3.** The second fixation element should be a diaphyseal half pin placed anterior to posterior on the distal (middle) ring. This pin is oriented at a 90 degree angle to the reference wire. The frame should be aligned orthogonal to the bone in both the coronal and sagittal planes. Once these two points of fixation are placed (proximal reference wire and distal half pin), the fixator ring positions are fixed. No further adjustments to ring positions will be possible.

pin can be placed at 90 degrees to the initial anterior to posterior half pin creating the maximal pin spread. Two additional half pins can be placed into the medial face of the tibia at 30 degrees angles between the first two pins to create the optimal divergence of pins. Avoid placing pins in the same plane, if possible.

If the desired construct is a two-ring frame, at least two additional half pins should be placed on the distal ring. The pins should be spread above and below the ring to cover as much length of the distal bone segment as possible. A straight medial to lateral half pin and a medial face half pin at 45 degrees will produce the optimal half pin divergence for three half pins.

On the proximal ring, a half pin can be placed just below the ring in an anteromedial to posterolateral direction. The final half pin will be placed in an anterolateral to posteromedial direction below the proximal ring. However, this pin should be placed after the tibial

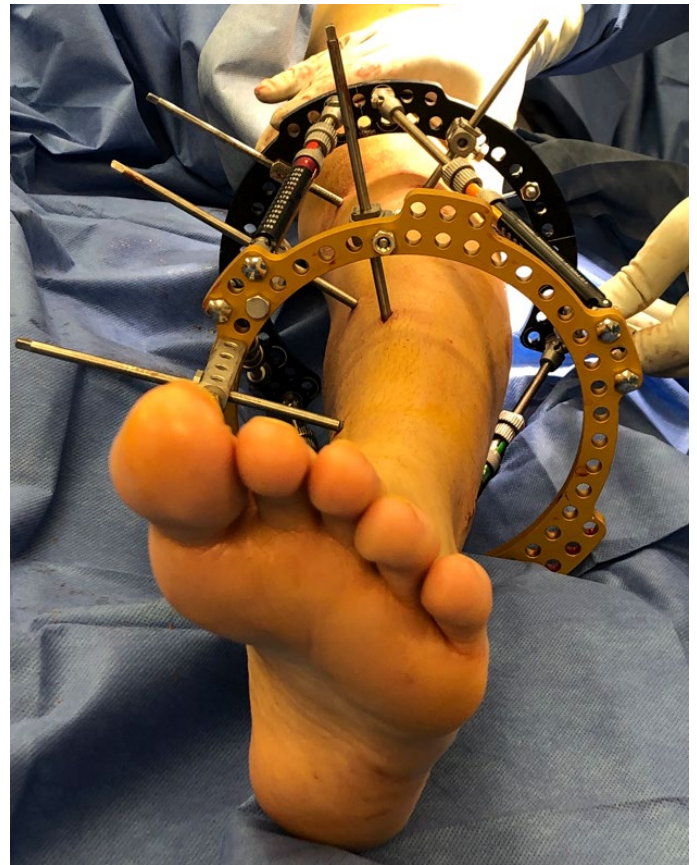osteotomy is completed. This will avoid any chance that the osteotomy will propagate into and compromise the integrity of the pin site. After the osteotomy has been completed, this pin can be placed very close to the osteotomy without concern. This allows the surgeon to achieve very stable fixation of the smaller proximal fragment (Figure 4).

The tibial osteotomy is performed as close to the deformity apex as possible. In many pediatric cases, the apex is at the level of the physis. Therefore, the osteotomy is placed as proximal as possible, just below the tibial tubercle. The tibial osteotomy technique should aim to minimize soft tissue stripping and the generation of heat. Oscillating saws are not recommended since they require a large incision and can burn the bone. Multiple drill holes connected by a handheld osteotome is the most commonly utilized percutaneous osteotomy technique. The greater the number of drill holes, the easier it will be to complete the osteotomy and to achieve a straight cut. Verify that the tibial osteotomy is complete by gently translating the two fragments relative to each other. This critical check prevents the embarrassment of discovering the osteotomy was incomplete two weeks later when the patient can't get the bone fragments to move.

At the end of the case, the pin and wire sites should be dressed with fixator-specific sponges or gauze dressings to apply compression to the pin sites and to minimize the amount of skin movement around the pin sites. Compression of the pin site helps to minimize the edema and/or hematoma formation at each site. If there is any visible skin tension around a pin or wire, it should be released at this time. Prior to leaving the operating room, double check that all of the articulations on the frame are tight and that the knee and ankle have full passive range of motion.

### Handling Difficulties

Even with the most thorough preoperative plan, things may not go entirely as expected in the operating room.



**Figure 4.** The final frame construct should have a combination of half pins and wires placed at multiple angles and spread out over the length of each bone segment. A minimum of two to three fixation elements should be attached to each ring.

The following tips can be used to help minimize any additional difficulties that you may encounter.

- 1) Placing the reference wire orthogonal to the bone is a critical first step to the procedure. Use the proximal tibial joint line as a visual guide for placing the wire. In some pediatric patients with severe deformity, the proximal tibial joint line may be difficult to visualize. In this case, the orientation of the distal femoral condyles can be used as a substitute guide for the reference wire orientation. An alternative option is to perform a knee joint arthrogram to better visualize the outline of the proximal tibial plateaus.
- 2) If the initial reference wire is not perfectly orthogonal, the frame can be mounted orthogonal to the bone

by using washers to push one side of the ring up or down until it is orthogonal. This avoids having to replace the reference wire multiple times.

- 3) After passing a wire, if it is not flush with the ring on one side or the other, do not bend the wire to the ring to attach it. Instead, build up to the wire from the ring with washers or a post. Bending the wire places tension on the soft tissues and can create an unintended deformity at the fracture/osteotomy site.
- 4) Pay attention that the ring position maintains adequate soft tissue clearance circumferentially at all times. Placing towels as a spacer between the ring and skin can help prevent inadvertent mounting of the ring too close to the skin.
- 5) A fibular osteotomy may not be necessary if the coronal deformity is larger than the sagittal deformity, there is less than 20 degrees of rotational deformity, and the planned lengthening is less than 2 cm.<sup>3</sup>
- 6) If the distal tibial-fibular syndesmosis needs to be stabilized, a transfixion wire or a screw can be used. The transfixion wire should be drilled posterolateral to anteromedial bi-cortically through the fibula and should exit safely through the medial face of the tibia. Placing a finger at the desired exit point while drilling will provide spatial feedback to avoid exiting in an unwanted area. A transfixion screw can be placed in a similar fashion using a guidewire and cannulated drill. The guidewire is drilled bi-cortically from the fibula to the tibia and exits the medial face of the tibia. A cannulated drill is placed over the wire and used to percutaneously drill from the tibia to the fibula. Be sure to check that the guidewire is centered in the fibula before drilling. A solid or cannulated screw can then be inserted along the drill path from the tibia to the fibula (author's preference) or from the fibula to the tibia. Drilling at a slight angle from inferior at the fibula to superior at the tibial exit point will create stronger fixation (tent peg concept).
- 7) Be cognizant of pin placement relative to the anticipated location of the struts connecting the rings. In the rings first method, the struts are not attached

when the ring is first attached to each bone segment. Don't place fixation in the path of a strut. Try to put the initial fixation outside the rings prior to attaching the struts. Once the struts are attached, fixation can be placed inside the rings out of the path of the now visible struts.

- 8) If planning to place a fixation element close to a strut, determine which direction the strut will move during the correction to avoid future impingement.
- 9) If the ring is inadvertently mounted with internal or external rotation, the degree of malrotation can be calculated. First, count the number of holes in the ring and divide that number into 360. This number represents the number of degrees between each hole. Then count the number of holes between your current center position and your desired center position. Multiply the number of holes by the calculated number of degrees per hole to determine the total amount of rotation. For example, if the ring has 36 holes, each hole represents 10 degrees of the complete circle. If the ring was inadvertently mounted with the center hole internally rotated two holes from the direct anterior position, then there is 20 degrees of internal rotation of the ring.

## Postoperative Management

The most common postoperative complication with hexapod external fixators is pin-site infection. While no particular pin site care regimen has been shown to be perfect, there are several basic strategies that should be employed to limit the risk of pin-site problems:

- 1) Irrigate each pin site intraoperatively after predrilling to remove any bone fragments from the soft tissue.
- 2) After the pin is inserted, immediately cover with a sponge or dressing to limit bleeding and swelling at the area.
- 3) Replace with new sterile sponges/dressings at the end of the case.
- 4) Limit the amount of motion of the skin around the pin by keeping a sponge/dressing on the periarticular half pins/wires throughout treatment.

- 5) Educate the patient/family on pin-site care and have frequent, regular checks of each pin site in the office or by photos sent electronically.
- 6) Plan to have redundant fixation elements in the initial frame construct so that if an infected pin or wire needs to be removed, the integrity of the frame stability won't be compromised.

Scheduling weekly evaluations of the regenerate/osteotomy healing during the distraction phase will help to keep the surgeon out of trouble. Frequent and regular assessment of the pin sites and the bone healing is important to adjust the correction speed and pin-site care. If the regenerate is healing quickly, the correction rate can be increased to prevent a premature consolidation. If the regenerate bone formation is poor, the correction speed can be decreased or stopped, if necessary. The regenerate bone should be visible by two to three weeks after surgery.

Once the distraction or adjustment phase is completed, the goal is to get the patient weight-bearing without assistance. Regular physical therapy can help advance the

weight-bearing as tolerated and provide feedback about the patient's progress. Radiographs to evaluate the bone healing should be obtained every few weeks until the surgeon feels the bone has adequately consolidated. Clinically, if the patient has a comfortable range of motion and is easily able to ambulate fully weight-bearing in the fixator without assistance, this is a good indication that the frame may be ready for removal.

## References

1. Standard SC, Herzenberg JE, Conway JD, et al. The Art of Limb Alignment, Ninth Edition. 2020 Rubin Institute for Advanced Orthopedics, Sinai Hospital of Baltimore.
2. Malik SS and Malik SS. External Fixation. In, Orthopaedic Biomechanics Made Easy. Cambridge University Press, Cambridge, UK 2015. P 180.
3. Eidelman M, Bialik V, Katzman A. The use of the Taylor spatial frame in adolescent Blount's disease: is fibular osteotomy necessary? *J Child Orthop* 2008;2:199-204.