

# Pediatric Femoral Head Osteonecrosis Secondary to Trauma, Sickle Cell Disease, and Corticosteroid Therapy

Harry K.W. Kim, MD<sup>1,2</sup> and William Z. Morris, MD<sup>1,2</sup>

<sup>1</sup>Center for Excellence in Hip, Scottish Rite for Children, Dallas, TX; <sup>2</sup>Department of Orthopaedic Surgery, UT Southwestern Medical Center, Dallas, TX

## Abstract:

Management of pediatric femoral head osteonecrosis (FHO) due to various etiologies remains a clinical challenge due to delayed diagnosis, limited evidence to guide treatment decision-making, and a lack of consensus on treatments to prevent the femoral head deformity. Since many review articles have been written on Legg-Calve-Perthes disease, this review focuses on pediatric FHO secondary to trauma, sickle cell disease, and corticosteroid therapy. Posttraumatic FHO is a serious complication that can occur following femoral neck fractures and traumatic hip dislocations in children. Sickle cell disease is the most common inherited blood disorder in the U.S. and is a common cause of multi-focal osteonecrosis in patients of African descent and from the sub-Saharan Africa, the Mediterranean, the Persian Gulf, and the Indian subcontinent. Corticosteroid-induced osteonecrosis in patients with acute lymphocytic leukemia is of particular interest since acute lymphocytic leukemia is prevalent in the pediatric population. The goal of this review is to educate the clinician on the epidemiology, pathophysiology, natural history, evaluation, and treatment considerations for pediatric FHO secondary to these conditions.

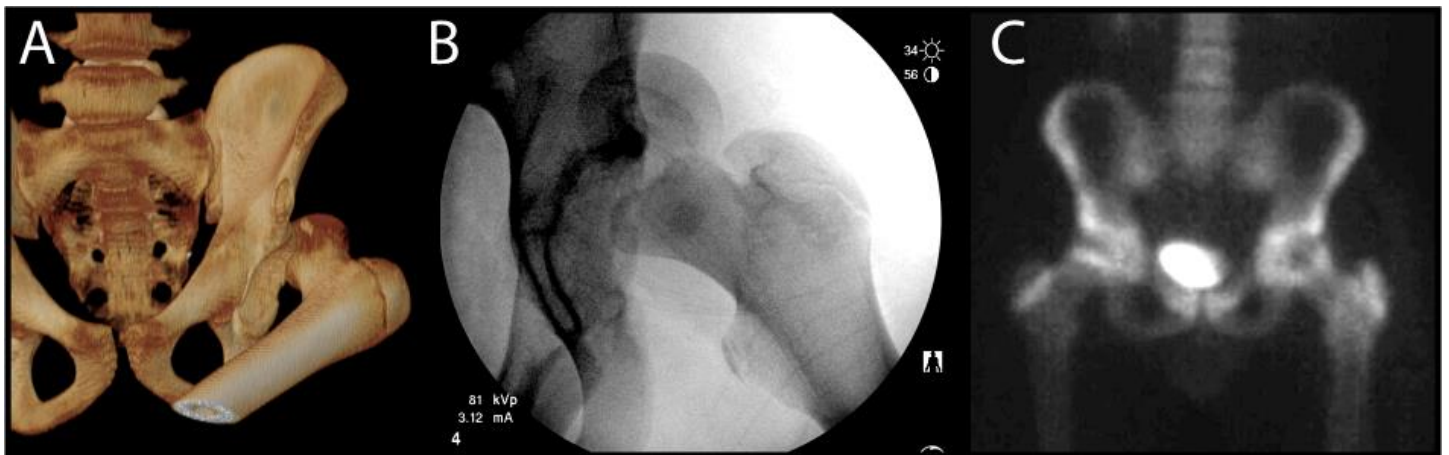## Key Concepts:

- Early diagnosis and treatment are essential for preventing the femoral head collapse and preserving the hip joint in pediatric FHO.
- Treatment approach should be tailored to the age of the patient, the extent of femoral head necrosis, and the status of the femoral head deformity.
- For younger patients with FHO, some treatment principles of Legg-Calve-Perthes disease are applicable, such as weight-bearing/activity restrictions and the nonoperative and operative treatment concepts of containment, as there is a greater potential for spontaneous healing and femoral head remodeling.
- FHO related to sickle cell disease or corticosteroid therapy is more common in adolescents than in younger children and is associated with poorer outcome.
- In teenage patients, a proactive treatment approach to prevent the deformity, such as multiple small drilling with the transplantation of bone marrow aspirate concentrate (BMAC), should be considered early.

## Introduction

Pediatric femoral head osteonecrosis (FHO) is potentially a devastating condition which can produce painful progressive osteoarthritis with patients requiring a total

hip replacement or hip fusion at a relatively young age. Pediatric FHO is a group of clinical entities which can be divided on the basis of pathogenic mechanism of osteonecrosis: idiopathic, traumatic, nontraumatic, and



**Figure 1.** A) Computed Tomography 3D reconstruction at outside hospital of a 14-year-old male who sustained a traumatic left hip dislocation during a football game. B) Intraoperative fluoroscopic image obtained during attempted closed reduction under anesthesia at outside hospital shows capital femoral epiphysiolysis. C) After patient underwent open reduction and internal fixation, a bone scan obtained at 6 weeks postoperatively demonstrates decreased uptake of the left femoral head on anterior-posterior view, consistent with FHO. (Treatment of this case continued in Figure 6.)

septic. Many review articles on pediatric idiopathic osteonecrosis, Legg-Calve-Perthes disease (LCPD), are available. Thus, this review focuses on pediatric FHO secondary to trauma, sickle cell disease, and corticosteroid therapy. The goal of this review is to educate the clinician on the epidemiology, pathophysiology, natural history, evaluation, and treatment considerations for pediatric FHO secondary to these conditions.

## Epidemiology

### Posttraumatic Femoral Head Osteonecrosis

Posttraumatic FHO is a serious complication that can occur following femoral neck fractures and traumatic hip dislocations in children. Femoral neck fractures are fortunately one of the less common pediatric injuries, estimated to represent < 1% of all fractures in children<sup>1,2</sup> but carry a high rate of FHO. Rates of FHO vary widely from 7–88% in the literature with the incidence of many studies closer to approximately 20%.<sup>1-9</sup> The risk factors for traumatic FHO include the location of the fracture, time to surgery, and age, with controversy regarding the risks associated with method of reduction, the use of capsular decompression, and pre and postoperative alignment.<sup>6,8,10,11</sup> Femoral neck fracture location is typically described using the Delbet classification<sup>12,13</sup> where

fractures are categorized as transphyseal (Type I), transcervical (Type II), cervicotrochanteric (Type III), or intertrochanteric (Type IV). A recent meta-analysis of studies comprising 360 cases of pediatric femoral neck fracture revealed the rates of FHO decreased with more distal fracture type (Type I – 38%, Type II – 28%, Type III – 18%, Type IV – 5%).<sup>9</sup> Time to reduction has been suggested as a risk factor with some studies showing delayed treatment increasing the rate of FHO.<sup>3,11</sup> Increasing age has been associated with increased risk of FHO with one meta-analysis utilizing logistic regression to demonstrate that older children were 1.14 times more likely to develop FHO for each year of increasing age.<sup>9</sup> Although some studies have suggested that open reduction may reduce the risk of FHO,<sup>6,8</sup> a meta-analysis found no association between reduction type and risk of FHO while a systematic review identified increased FHO following open reduction (though they acknowledge this is confounded by the severity of the injury between groups).<sup>9,11</sup> Similarly, increased displacement has been associated with increased risk of FHO, though this factor did not remain significant in multivariate analysis.<sup>9,10</sup>

Following traumatic hip dislocation, rates of FHO range from 3 to 15%.<sup>14-16</sup> However, during attempted closed reduction of the hip, epiphysiolysis may occur,

creating an injury similar to a Delbet I femoral neck fracture. With epiphysiolysis, the rate of FHO is near 100% (Figure 1).<sup>17,18</sup> While there is less literature on FHO following traumatic hip dislocation, Mehlman et al.<sup>15</sup> reported on a series of 42 traumatic hip dislocations in children with a 12% rate of subsequent FHO. The only significant predictor of FHO was the time to reduction with > 6 hrs presenting a 20-fold increased risk of FHO.

### Sickle Cell Disease

Sickle cell disease (SCD) is the most common inherited blood disorder in the U.S. and is a common cause of multi-focal osteonecrosis in patients of African descent and from the sub-Saharan Africa, the Mediterranean, the Persian Gulf, and the Indian subcontinent. The sickle cell trait (asymptomatic carrier state) is not associated with osteonecrosis. The most common locations involved are the femoral head followed by the humeral head and the distal femur and proximal tibia around the knee.<sup>19</sup> The incidence and prevalence of FHO in SCD is higher in adults compared to the pediatric population. In a large study of 2590 patients over 5 years of age, the incidence was 3.9 cases per 100 patient-years in the  $\geq 35$  age group compared to 2.1 cases per 100 patient-years in the 5 to 14 age group. The prevalence was 21.9% and 32.5% for the 35-44 and  $\geq 45$  age groups compared to 1.3% and 4.6% for the 5 to 9 and 10-14 age groups, respectively.<sup>20</sup> The overall prevalence was 9.8%. The incidence and the prevalence of FHO also vary depending on the hemoglobin genotype (SS, SC, S $\beta^0$ , S $\beta^+$ ). In the pediatric group, the incidence was highest among patients with HbSS genotype and  $\alpha$ -thalassemia (3.6 cases per 100 patient-years) and S $\beta^0$  genotype (4.3 cases per 100 patient-years). Frequent vaso-occlusive crises, a higher hematocrit, lower mean corpuscular volume, and lower aspartate aminotransferase level were risk factors for FHO in the patients with HbSS genotype. The duration of follow-up, the age of patients included in the study, and diagnostic imaging (x-rays vs. MRI) can also affect the reported prevalence of osteonecrosis.

In a population-based cohort study using California's Office of Statewide Planning and Development discharge databases (1991-2013) consisting of 6237 patients with SCD, 22% developed FHO at a median age of 27 years.<sup>21</sup> The cumulative incidence of FHO to age 30 years was higher among SCD patients with more severe disease, defined as  $\geq 3$  hospital or emergency department admissions/year (24% vs. 8% in less severe) and those with antecedent acute chest syndrome (ACS) (18% vs. 8% without prior history of ACS).

### Corticosteroid-Induced Osteonecrosis

In the pediatric population, corticosteroids are used for various conditions including systemic lupus erythematosus (SLE), inflammatory disorders, skin disorders, asthma, organ transplantations, bone marrow transplantation, head or spinal cord injury, and as a part of chemotherapy for various malignancies including acute lymphocytic leukemia (ALL) and lymphoma. The incidence of FHO associated with corticosteroid therapy depends on the underlying disease, age, mean, and maximum daily dose, cumulative dose, and the route of administration.<sup>22</sup> Topical or inhaled steroid therapy alone has not been reported to produce FHO. In the adult population, corticosteroid-induced osteonecrosis is considered one of the most common forms of FHO.

The impact of corticosteroid therapy on the pediatric population is less since some of these conditions are less prevalent in children. For instance, SLE is most prevalent in the > 20 age group.<sup>23</sup> Moreover, the rate of osteonecrosis in the pediatric age group, defined as age < 15 in the study, is lower in conditions like SLE and ALL.<sup>23,24</sup> In one prospective study of SLE patients monitored with MRI, FHO did not develop in any patients younger than age 14 years of age treated with corticosteroids.<sup>23</sup> Further, asymptomatic FHO in adult SLE patients has the ability to spontaneously repair and has a relatively low prevalence of femoral head collapse.<sup>25,26</sup>

Corticosteroid-induced osteonecrosis in patients with acute lymphocytic leukemia (ALL) is of particular inter-

est since ALL is prevalent in the pediatric population. While incorporation of high dose dexamethasone to chemotherapy regimens has produced a significant improvement in event-free survival, this success has been at a cost of increased multifocal osteonecrosis. Overall incidence of osteonecrosis reported by various studies ranged from 1 to 10%, 3 to 5 years after diagnosis among multicenter trials.<sup>27</sup> While corticosteroid dosing and chemotherapy protocol likely impacted the incidences, a wide variability may also be contributed by criteria and stringency used for the diagnosis of osteonecrosis.<sup>28</sup> The quality of most published studies on the incidence of osteonecrosis in ALL is thought to be relatively poor as many studies did not describe the radiological method used to diagnose osteonecrosis and/or did not use a validated osteonecrosis classification system.<sup>29</sup>

Most studies report significantly higher risk of osteonecrosis among older (age > 10) compared to younger (age < 10) patients with ALL. Analysis of osteonecrosis incidence and risk factors from 22 clinical trials of ALL found adolescent age as the most significant risk factor, with patients > 10 years old at the highest risk.<sup>27</sup> In one trial, ALL patients < 10 years of age at diagnosis had cumulative risk of 0.2% while those > 10 and > 15 years of age at diagnosis had substantially higher cumulative risks of 8.9% and 16.7%, respectively.<sup>24</sup> In a prospective study, the median age at diagnosis of ALL in patients with osteonecrosis was 13.5 years, compared with 4.7 years in those without osteonecrosis.<sup>30</sup> In the study, female sex was also identified as an independent risk factor for osteonecrosis. The use of dexamethasone in comparison to the use of prednisone was associated with a significantly higher incidence of osteonecrosis.<sup>31</sup> For patients aged 10 years and older with a rapid response to induction treatment, the use of alternate-week dexamethasone during phases of delayed intensification significantly reduced osteonecrosis incidence compared with continuous dexamethasone, especially in those aged 16 years and older, in a randomized controlled trial.<sup>32</sup>

In the Childhood Cancer Survivor Study which assessed adult survivors of childhood hematologic and

nonhematologic cancers, a history of corticosteroid therapy, radiation, allogeneic stem-cell transplantation (necessitating long-term corticosteroid therapy), and adolescent age at diagnosis were major risk factors for the development of osteonecrosis.<sup>33</sup> Dexamethasone therapy, with or without prednisone, conferred a higher rate ratio of osteonecrosis than prednisone alone.

## Pathophysiology

### Posttraumatic Osteonecrosis

In contrast to skeletally mature patients whose vascular supply to the femoral head may pass across the metaphysis into the epiphysis, pediatric patients with an open proximal femoral physis rely on arterial supply from the medial femoral circumflex artery and the artery of the ligamentum teres.<sup>34-36</sup> As the medial femoral circumflex vessel becomes intracapsular as the lateral ascending branches, it is consequently at risk to injury through direct trauma at the time of injury, tension or kinking due to displacement of the fracture, compression due to intracapsular hematoma, or iatrogenic injury during treatment. Injury through any of these mechanisms can compromise vascular supply to the femoral head. This concept is consistent with the literature demonstrating the increased risk of osteonecrosis with transphyseal and transcervical femoral neck fractures (Delbet I and II, respectively) compared to extracapsular fractures.<sup>9,11</sup> It is also consistent with the literature supporting that increased initial displacement is associated with increased risk of osteonecrosis.<sup>9,10</sup> Finally, the risk of osteonecrosis following traumatic hip dislocation provides evidence that tension or kinking of the epiphyseal vessels may pose a risk to the perfusion of the epiphysis as prolonged time to reduction > 6 hrs increases the risk of FHO 20-fold.<sup>15</sup>

### Sickle Cell Disease

SCD is an inherited hemoglobinopathy caused by a homozygous  $\beta$ -globin gene mutation (HbSS genotype) or double heterozygous mutations: hemoglobin SC disease (HbSC genotype), hemoglobin S- $\beta^0$ -thalassemia (HbS $\beta^0$  genotype), and hemoglobin S-  $\beta^+$ -thalassemia (HbS $\beta^+$

genotype).<sup>20,37</sup> In the cases of HbSS, single point mutation of  $\beta$ -globin gene produces valine substitution of glutamic acid and both copies of the gene are affected (homozygous) in contrast to the patients with sickle cell trait who only have one copy of the gene involved (heterozygous). The mutation alters the red blood cell shape to become sickled shaped under low oxygen tension, making the cells become stiff and sticky.<sup>38</sup> Increased adhesiveness of the sickled red cells is postulated to make them more likely to become static during the transit through the microvasculature, especially in the areas of sluggish flow, and cause microvascular occlusions. Vascular occlusion produces hypoxia that further triggers sickling in the hypoxic region. Inflammation upregulates the expression of adhesion molecules on the endothelial cells and is believed to further promote vascular obstruction and ischemia. Vascular obstruction has been proposed to increase the intraosseous pressure of the femoral head and subsequent osteonecrosis.

### **Corticosteroid-Induced Osteonecrosis**

The pathophysiology of corticosteroid-induced osteonecrosis is complex.<sup>39</sup> A combination of direct and indirect mechanisms is involved in cell death and vascular disruption. Apoptosis of osteocytes has been proposed as one of the direct mechanisms of corticosteroid-induced osteonecrosis.<sup>40,41</sup> The indirect mechanisms involve hyperlipidemia, hypercoagulation, and hypofibrinolysis. It has been shown that corticosteroids increase serum lipids and induce adipocyte hypertrophy which may promote fat emboli and impede blood flow within the bone.<sup>42</sup> Corticosteroids also promote hypercoagulability by decreasing fibrinolysis through reductions in tissue plasminogen activator (t-PA) activity and increasing plasma plasminogen activator inhibitor-1 (PAI-1) antigen levels. Upregulation of endothelial vasoactivity by a corticosteroid in bone is also thought to contribute to an increase in the intraosseous pressure and a decrease in the vascular outflow from the femoral head. Furthermore, it is postulated that corticosteroids contribute to the endothelial dysfunction or thrombus formation by inducing endothelial apoptosis.<sup>43</sup>

### **Pathogenesis of Femoral Head Deformity**

Development of femoral head deformity dramatically affects the outcome of FHO. Thus, prevention of femoral head deformity is a primary goal of orthopaedic treatment and requires better understanding of why necrotic femoral heads deform. Studies using a large animal model of ischemic osteonecrosis reveal that the pathogenesis of femoral head deformity following ischemic osteonecrosis is complex and involves several factors, such as, alteration of material and mechanical properties of the trabecular bone due to osteonecrosis, pathological repair process in the inflammatory, necrotic bone microenvironment, and the degree of mechanical loading of the affected bone.<sup>44</sup> In the early avascular phase of the disease, experimental studies show increased calcium content of the necrotic bone, especially in the subchondral region, which makes the bone more brittle and prone to microdamage accumulation with normal loading of the joint.<sup>45</sup> Increased calcium content also explains why the necrotic bone appears sclerotic in the initial stage of osteonecrosis. Furthermore, it explains why the subchondral region is more prone to fracture and collapse in the early stage. In the region of the necrotic bone bordering on the viable bone, increased osteoclastic bone resorption is seen with no accompanying new bone formation.<sup>46</sup> It is believed that the imbalance of bone resorption and bone formation is partly due to the necrotic bone microenvironment which initiates and maintains the chronic inflammatory repair response. The net bone loss contributes to the mechanical weakening of the femoral head in the area of resorption. One important aspect of femoral head deformity is continue loading of the necrotic femoral head which is accumulating microdamage and undergoing bone resorption. In an experimental study, non-weight-bearing has been shown to decrease the femoral head deformity.<sup>47</sup>

### **Natural History**

#### **Posttraumatic Osteonecrosis**

Following femoral neck fracture or traumatic hip dislocation, if FHO is present, it is generally diagnosed by 12

months post-injury.<sup>10,15</sup> In a series of 70 pediatric femoral neck fractures, Spence et al.<sup>10</sup> reported a rate of FHO of 29% (20/70) with a mean time to diagnosis of 7.8 months (range 2.7 to 31.4 months). In a large series of 42 traumatic pediatric hip dislocations, Mehlman et al.<sup>15</sup> observed a rate of osteonecrosis of 12% (5/42) with radiographic evidence of FHO apparent in all cases between 2-12 months. There is limited long-term follow-up data on the natural history of post-traumatic FHO in pediatric patients, primarily reported indirectly through long-term outcomes after pediatric femoral neck fractures. One long-term study of 41 pediatric patients with femoral neck fracture and 13 to 23 years of follow-up revealed that 2/10 cases with osteonecrosis had gone on to total hip arthroplasty (THA) and that the other eight had femoral head collapse leading to late osteoarthritis.<sup>4</sup> Another series of 53 pediatric femoral neck fractures (with FHO rate 40%) was followed for mean 9.4 years post-injury and 34/55 were found to have developed arthritic changes within this period.<sup>48</sup> Finally, in a series of 19 patients with pediatric hip fractures and mean follow-up 16 years, 47% (9/19) had developed osteonecrosis and 44% (4/9) of these patients had undergone hip arthroplasty by 11 years post-injury.<sup>49</sup> These studies suggest that without intervention, post-traumatic FHO portends a poor prognosis.

**Sickle Cell Disease (SCD)**

The natural history of patients with childhood FHO due to SCD is poor with deterioration of hip function over time.<sup>50</sup> In a retrospective study of 52 patients (95 hips) who had SCD and FHO in childhood, 80% of the hips were painful and had permanent damage with decreased mobility, limb-length discrepancy, and an abnormal gait at an average follow-up of 19 years after the onset of

**Table 1. Steinberg Classification of Adult FHO**

Stage	Description
0	Normal x-ray, bone scan, and MRI
I A: Mild B: Moderate C: Severe	Normal x-ray Abnormal bone scan and/or MRI < 15% head affected 15-30% head affected > 30% head affected
II A: Mild B: Moderate C: Severe	Cystic and sclerotic changes < 15% head affected 15-30% head affected >30% head affected
III A: Mild B: Moderate C: Severe	Subchondral collapse/fracture without flattening < 15% of articular surface 15-30% of articular surface > 30% of articular surface
IV A: Mild B: Moderate C: Severe	Femoral head flattening < 15% head affected and < 2 mm head depression 15-30% head affected or 2-4 mm head depression > 30% head affected
V A: Mild B: Moderate C: Severe	Joint space narrowing or acetabular involvement
VI	Advanced degenerative changes

the disease. At an average age of 31 years, 15 out of the 95 hips had an operation for a progressive disability and 60 out of the 95 hips had major problems because of pain. Loss of femoral head sphericity of varying degree, narrowing of the joint space, and growth disturbance of

the proximal femur were commonly observed. The mean Iowa hip-rating score at the most recent follow-up examination was 73 points (range 30 to 100). In general, bilateral hip involvement is common (54% in one study), which can increase the morbidity, and involvement of multiple sites (shoulder and knee) is also common (44% in one study), which become symptomatic and restricted in motion.<sup>20</sup>

The natural history of adult patients with SCD and symptomatic FHO without a collapse further highlight the poor outcomes associated with this condition. The probability of progression was high with 87% collapsing within 5 years.<sup>51</sup> In 121 asymptomatic pre-collapse hips (contralateral to a symptomatic hip identified by MRI in adults with SCD, mean age of 26 years, and range 18-31), pain developed in 91% and collapse occurred in 73% at the mean duration of follow-up of 14 years.<sup>51</sup> The percentage of hips becoming symptomatic and having collapse was higher with later stages of osteonecrosis (Table 1). The risk of progression also correlated with the extent of the femoral head involvement. Those hips with mild involvement (< 15%) had significantly longer durations of survival before collapse than the hips with moderate (15-30%) or severe (> 30%) involvement. However, even in the hips with mild involvement, the survival rate was less than 40% in Kaplan-Meier analysis, indicating that the extent of involvement had a limited effect on the final clinical outcome. In a systematic review of untreated asymptomatic FHO in adults, the patients with SCD had the highest rate of femoral head collapse (73%), whereas those with SLE had the most benign course (7%).<sup>26</sup> The study clearly demonstrates the importance of disease-specific factors on the outcome of FHO. In their conclusion, it was advised that given the high prevalence of complications after THA in patients with SCD, consideration should be given to early surgical intervention with other procedures in an attempt to retard progression of the disease.

### **Corticosteroid-Induced Osteonecrosis**

The natural history of corticosteroid-induced osteonecrosis largely depends on the age and the size of

osteonecrosis involvement. In general, patients < 10 years old, patients with smaller lesions (< 30% of femoral head), and patients with lesions located away from the loadbearing region of the femoral head have better prognosis.<sup>52</sup> In a study of 80 pediatric and young adult patients with leukemia or lymphoma and FHO (median age at diagnosis 14.6 years, range 2 to 20), large femoral head involvement was significantly associated with joint collapse and need for joint arthroplasty at a median follow-up of 40 months (range 1-175 months).<sup>52</sup> The worst prognosis was associated with lesions occupying > 30% of the femoral head volume; 80% of hips with these lesions collapsed within 2 years of diagnosis and 50% required arthroplasty. Twenty-nine percent of the patients had joint arthroplasty at a median of 1.3 years (range 0.5 to 8.6) after the diagnosis of osteonecrosis; median age at time of first arthroplasty was 20 years (range 15 to 35). This and other studies suggest that small lesions detected with screening MRIs may resolve or fail to progress, whereas larger lesions involving the subchondral region of the femoral head and knee often leads to collapse, deformity, and osteoarthritis with debilitating pain and disability.<sup>53</sup>

In the Childhood Cancer Survivor Study which assessed adult survivors of various childhood cancers, including hematologic and non-hematologic cancers, the most common site for osteonecrosis was the hips, followed by the shoulders and knees.<sup>33</sup> Osteonecrosis caused difficulty with at least one activity of daily living, such as indoor walking, climbing upstairs, rising from a chair, putting on pants, reaching into low cupboards, and opening containers, in 57% of survivors and at least two activities in 44% of survivors.<sup>54</sup> Thirty-three percent of survivors with osteonecrosis had difficulty walking inside, and 41% had pain at rest.

A cross-sectional study of adult survivors of childhood leukemia and lymphoma ( $\geq 10$  years from the diagnosis and  $\geq 18$  years old) from the St. Jude Lifetime Cohort Study with (n=135) and without (n=1560) osteonecrosis found impaired physical performance and reported reduced quality of life (QOL) compared with community

controls (n=272).<sup>55</sup> Interestingly, similar deficits in functional outcome, social role attainment (annual household income and live independently), and QOL (SF-36) were found in the survivors regardless of their history of osteonecrosis. However, the survivors requiring surgery for osteonecrosis (n=28) were most at risk for impairments in all these outcomes and had the greatest loss of function.

A retrospective review of 18 patients (29 hips) under 21 years of age with FHO and childhood onset malignancy found that the mean time from initiation of chemotherapy to onset of pain was 18.8 months (8.0-49.1),<sup>56</sup> the mean time from development of pain to diagnosis of FHO was 3.9 months (-13.1 to 25), and the mean time from initiation of chemotherapy to diagnosis of FHO was 22.7 months (9.0-54.1). At the time of diagnosis, 16/18 patients (21/29 hips) had already progressed to femoral head collapse indicating the urgent need for more prompt diagnosis and referral to an orthopaedic surgeon. Screening with MRI may be warranted for children undergoing chemotherapeutic regimens for malignancy to prevent delay in the diagnosis and management of FHO so that joint preservation remains a treatment option.

## Screening

Early diagnosis and treatment are essential for preventing the femoral head collapse and preserving the hip joint in patients with FHO. Since not all patients with SCD or patients with ALL exposed to high-dose corticosteroid regimen develop osteonecrosis, identification of biomarkers for osteonecrosis is of clinical importance as it may facilitate early diagnosis and treatment. Furthermore, it may identify patients who are at a high risk for developing osteonecrosis due to corticosteroid therapy and thus allow more cautious dosing and monitoring for the development of osteonecrosis. To this end, various genetic polymorphisms have been identified as risk factors; however, the results have not been confirmed by follow-up studies and their predictive value remains uncertain.<sup>57,58</sup> A recent genome-wide association study of 2285 children with ALL identified single nucleotide polymorphism (rs10989692) near the glutamate receptor

locus as a risk factor for osteonecrosis.<sup>59</sup> Further studies, however, are needed to define the predictive value of the polymorphism for osteonecrosis in ALL patients.

In a single-center retrospective study of 59 children with SCD and FHO, the hemoglobin to hematocrit ratio was found to be a strong predictor of osteonecrosis (OR=5.17), especially in the patients with HbSS genotype (OR=8.65). Further studies are warranted to confirm this interesting finding and to define its predictive role in the care of these patients.<sup>60</sup>

## Diagnostic Imaging

Plain radiography is the initial imaging modality of choice for diagnosis and management of FHO because of its accessibility and low cost. Other imaging modalities, such as MRI, CT, and bone scintigraphy may be obtained for various indications. In general, MRI has become the multi-planar imaging of choice for assessment and staging of FHO due to its high sensitivity and specificity and the availability of specific sequences to assess the articular cartilage, marrow changes, vascularity, synovitis, and the soft tissues in the hip joint, such as the labrum.

## Plain Radiography

Radiography is the first-line imaging modality which is useful for assessing the structural changes to the femoral head and monitoring the progression of FHO. Antero-posterior (AP) pelvis and frog-leg lateral views are recommended in patients with SCD and corticosteroid-induced osteonecrosis as they can have bilateral involvement. In teenagers with FHO, Waldenstrom radiographic staging used in children with LCPD is not applicable as older patients lack characteristic fragmentation and reossification stage changes seen in children with LCPD. Adult staging systems for FHO, such as the Steinberg (also known at the University of Pennsylvania system, Table 1) and the modified Association Research Osseous Circulation (ARCO) classification system, that assess the amount of femoral head involvement, collapse, and osteoarthritic changes may be more relevant for treatment decision-making and prognostication in teenagers with FHO.<sup>61,62</sup> In general, plain radiography



should be supplemented by MRI for accurate staging and assessment of location and size of the lesion and for patients with normal radiography who are highly suspected of having FHO.

### Magnetic Resonance Imaging

MRI is the multiplanar imaging of choice for staging of FHO and for assessment of location and size of the lesion. MRI is also useful for the assessment of articular cartilage, hip joint synovitis, and soft tissues in the joint. The conventional MRI sequences include T1 and T2 weighted imaging. The presence of well circumscribed low-intensity band in the subchondral region on T1-weighted imaging is pathognomonic of osteonecrosis. The low-intensity band depicts the reactive changes in the interface of the necrotic and the reparative zone. On T2-weighted imaging, the double-line sign consisting of a high-signal intensity inner rim and a low-signal intensity outer rim is characteristic of osteonecrosis. It is important to note that sagittal view on MRI provides more accurate assessment of the femoral head collapse.<sup>63</sup>

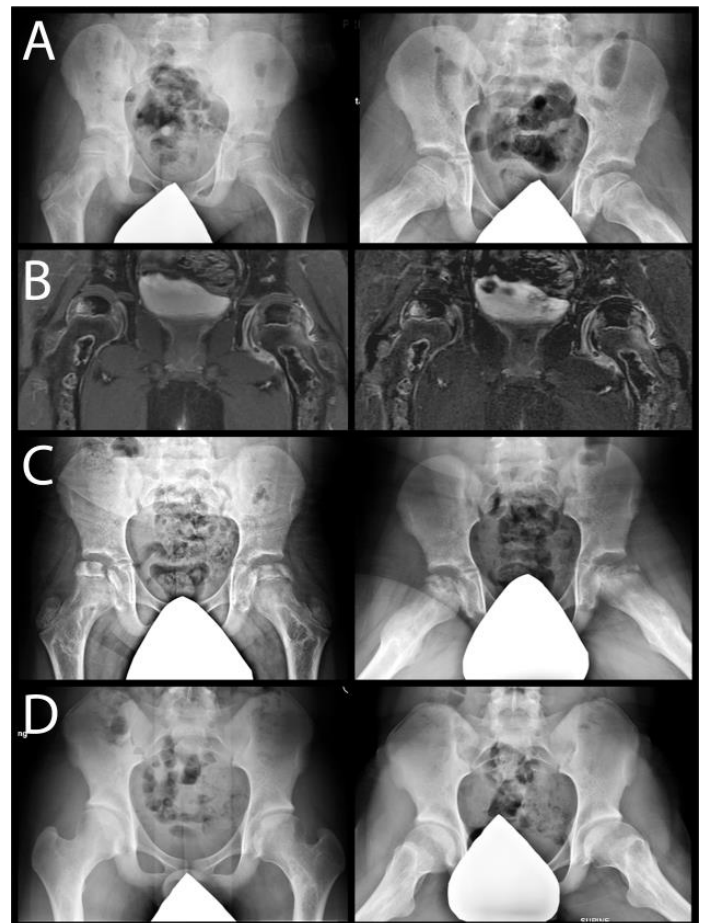
Gadolinium-enhanced MRI (also known as the perfusion MRI) has been shown to better delineate the area of hypoperfusion and provide early prognostication in LCPD.<sup>64,65</sup> We have found perfusion MRI to be useful for delineating the area of hypoperfusion in patients with FHO due to other etiologies (see MRI images in Figures 2-5).

### Computed Tomography

CT is useful for delineating the subchondral fracture and bony changes to the femoral head. CT has been shown to be more sensitive for the detection of subchondral fractures than MRI.<sup>66,67</sup> With the advancement of MRI bone sequences, such as T1 spoiled gradient-echo (T1SGRE) and ultra-short echo time (UTE) sequences, CT-like images obtained using MRI may become comparable to CT in the future.<sup>68</sup>

### Bone Scintigraphy

Bone scan has been superseded by MRI which has higher sensitivity and specificity and provides better



**Figure 2.** A) X-rays of a 10-year-old male with ALL undergoing chemotherapy. B) Mid-coronal post-contrast (right) and subtraction (left) images (also known as perfusion MRI) of bilateral femoral heads show central region of hypoperfusion, left hip synovitis and synovial hyperemia, and metaphyseal and diaphyseal areas of osteonecrosis. The patient was treated nonoperatively with activity and weight-bearing restrictions. C) X-rays at age 11. D) X-rays at age 16.

assessment of other features of FHO. Bone scan, however, is still useful in cases where metal hardware in the femoral head, such as after femoral neck fracture fixation (Figure 1), would preclude MRI due to metal artifact obscuring the pathology.

### General Treatment Considerations

There is no established treatment algorithm for pediatric patients with FHO due to trauma, SCD, or corticosteroid therapy. A limited availability of evidence to guide treatment decision-making in the literature imposes a clinical challenge for surgeons taking care of

these patients. Most of the reported studies are also retrospective in nature with small numbers of patients from single center and relatively short follow-ups. Thus, the treatment discussion outlined below is based on limited studies and information gained from studies on LCPD. Furthermore, given that older patients (age > 10) with SCD or exposed to corticosteroid therapy are at a greater risk for developing FHO than younger patients (age < 10), the knowledge gained from adult FHO is borrowed to guide the treatment of teenagers presenting with FHO.

For younger patients with FHO, some treatment principles of LCPD are applicable, such as weightbearing/activity restrictions and the nonoperative and operative treatment concepts of containment, as there is a greater potential for spontaneous necrotic bone healing and femoral head remodeling in the younger age group (Figure 2).

In older patients, the affected femoral head is more likely to progress and collapse leading to osteoarthritis, unless the necrotic area is small or away from the subchondral or weight-bearing region of the femoral head. Thus, proactive treatment approach to prevent or decrease the progression of deformity through treatments used in adult FHO, such as core decompression or multiple small drilling with the transplantation of bone marrow aspirate concentrate (BMAC) or re-directional osteotomy, should be considered early. To this end, high suspicion and early screening of older patients at risk for FHO using MRI should be considered.

Since SCD and corticosteroid-induced osteonecrosis can involve multiple sites, comprehensive clinical evaluation is important. Knee, ankle, and shoulder are commonly affected. Shoulder osteonecrosis is an underappreciated adverse late effect of corticosteroid therapy in children treated for leukemia/lymphoma which can limit quality of life, functionality, and the use of crutches for weight relief.<sup>69</sup> Shoulder pain and disability can be improved with treatment, such as physiotherapy, intraarticular injection, core decompression, and hemiarthroplasty in most patients with shoulder osteonecrosis.

## **General Considerations of Leukemic Patients with FHO**

Management of leukemic patients with FHO requires close coordination of care between oncologist, orthopedic surgeon, and physiotherapist.<sup>70,71</sup> Treatment decision and timing of intervention must not only consider osteonecrosis-related factors, such as stage, size, and collapse of the lesion, but also medical and chemotherapy-related factors, such as patient's overall health, phase of chemotherapy, response to chemotherapy, and adverse effects from chemotherapy (e.g., pancytopenia/neutropenia, cardiomyopathy). The details of surgical treatment and recovery should also be discussed with the oncologist. Given increased risk of infection and potential poor healing related to cancer and chemotherapy, less invasive procedures, such as core decompression or multiple epiphyseal drilling, are preferred. Pediatric Health Information System (PHIS) data from 43 freestanding children's hospitals (1999 to 2011) revealed the absence of postoperative mortality or ICU-level resource utilization suggesting that surgical intervention for osteonecrosis can be performed safely during maintenance therapy for ALL.<sup>72</sup>

## **General Considerations of SCD Patients with FHO**

Preoperative planning should carefully consider pain management, prevention of sickle cell crisis, oxygenation, hydration, and anemia. Careful intraoperative monitoring and proactive management of pain, oxygenation, fluid shifts, decreased body temperature, and acidosis are essential to avoid sickle cell crisis and complications.<sup>19</sup> A panel of experts recommends that red blood cell transfusion be used in all adults and children with sickle cell anemia to bring their preoperative hemoglobin level to 10 g/dL prior to surgical procedures involving general anesthesia.<sup>37</sup> A RCT demonstrated a lowered risk of postoperative complications including acute chest syndrome in persons with SCD undergoing medium risk surgery when their preoperative hemoglobin level was increased to 10 g/dL.<sup>73</sup>

## Medical Therapy

While there is no established medical therapy for FHO, numerous studies on systemic bisphosphonate therapy for FHO have been reported and are discussed below. For SCD, the impact of hydroxyurea therapy is notable since some evidence suggest improvement of the natural history of FHO in these patients.

### Bisphosphonate Therapy

Systemic bisphosphonate therapy is one of the most studied pharmacologic therapy for adult FHO.<sup>74</sup> Various pre-clinical studies have shown positive effects of bisphosphonate therapy on preventing or minimizing the femoral head deformity and preserving the bone volume in various animal models of osteonecrosis including juvenile FHO models.<sup>75</sup> One cautious note regarding these preclinical studies is that many animal studies are performed under optimized conditions, such as initiation of treatment shortly after the induction of osteonecrosis, optimized drug dosing, and short follow-up duration. Thus, these proof-of-concept studies may not be directly comparable to clinical settings where these treatment variables cannot be as controlled. A recent meta-analysis of seven published clinical trials of systemic bisphosphonate therapy for adult FHO found no significant difference in pain control, Harris hip score, radiographic progression, and rate of THA in the bisphosphonate therapy vs. control group.<sup>74</sup> One caveat to systemic dosing of bisphosphonate is that because of lack of blood flow to the necrotic region of the femoral head, local bioavailability of the drug may not be optimal. Experimental studies show that systemic administration of bisphosphonate is ineffective for local bioavailability of bisphosphonate in the necrotic region and a local intraosseous delivery was more effective.<sup>76,77</sup> This may partly explain why systemic bisphosphonate therapy has not shown to prevent disease progression in patients with osteonecrosis. There is also concern that bisphosphonate therapy decreases bone resorption and remodeling of the necrotic bone with retention of hypermineralized necrotic bone with abnormal mechanical properties and lack of new bone formation.<sup>78</sup>

In pediatric FHO, several small single-center studies of patients with osteonecrosis as a complication of chemotherapy for ALL found improvements in the pain, analgesic requirement, and function in the patients who received systemic bisphosphonate therapy (pamidronate).<sup>79-82</sup> Radiographic benefit of the therapy, however, could not be demonstrated. A prospective case series of traumatic osteonecrosis due to unstable SCFE, hip fracture, or dislocation in adolescents showed that the patients treated with intravenous pamidronate or zoledronic acid did better than expected from historical controls at the minimum follow-up of 2 years. Nine out of 17 patients had a spherical femoral head and 14 out of 17 patients were pain free. The mean Harris hip score, Iowa hip rating, and global PODCI score were 91.2, 92.1, and 91.5, respectively.<sup>83</sup> This study, however, did not have a control group.

### Hydroxyurea Therapy for SCD

Hydroxyurea (HU) therapy was approved by FDA in 1998 for adult patients with SCD to prevent pain crisis.<sup>84</sup> It significantly improved the clinical course of SCD by reducing the frequency of vaso-occlusive crisis, acute chest syndrome, and transfusions, and by reducing the number of hospitalizations for vaso-occlusive crisis in children and adults with SCD.<sup>85</sup> HU therapy works by improving the blood rheology, improving the RBC deformability by increasing the proportion of fetal hemoglobin (HbF) level and decreasing the proportion of HbS level inside the RBCs.<sup>86</sup> Other benefits such as lowering the number of circulating leukocytes and reticulocytes, decreasing their expression of adhesion molecules, and increasing red blood cell size (higher mean corpuscular volume) may contribute to increasing blood flow and reducing vaso-occlusion.<sup>37</sup> RBCs are less fragile to hemolysis, survive longer in the circulation and thus reduce anemia. In addition, nitric oxide released directly from hydroxyurea metabolism may contribute to local vasodilation. Long-term hydroxyurea therapy is well tolerated by pediatric patients with SCD while providing sustained hematologic efficacy with apparent long-term safety.<sup>87</sup>

The effect of HU therapy on the incidence and progression of FHO is controversial as there are conflicting reports on the role of HU therapy on the pathogenesis and outcome of FHO based on small, single-center studies. A population-based cohort study using California's Office of Statewide Planning and Development discharge databases does show decreased incidence rates for FHO across all age groups in the post-HU era (2001-13) compared to the pre-HU era (1991-2001), however, a causal relationship between HU therapy and FHO outcome remains unclear.<sup>21</sup>

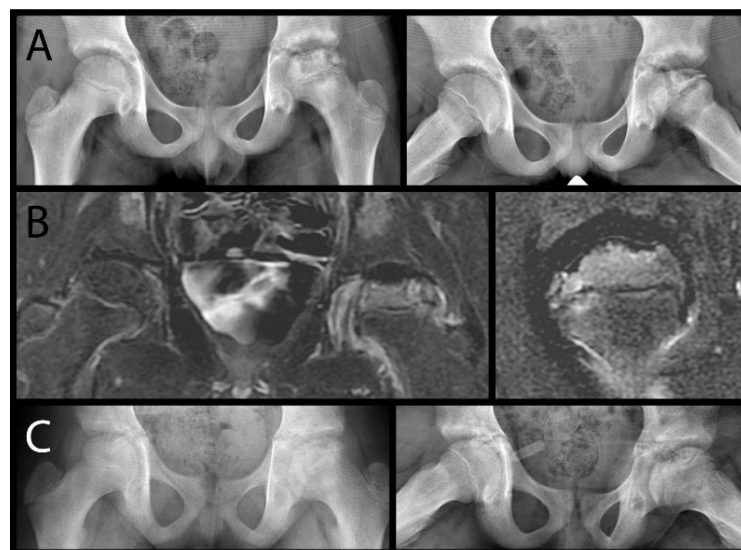
### Nonoperative Treatment

Early institution of non-weight-bearing using crutches or walker is considered the first line of treatment for FHO while MRI and surgical treatment are being planned. In patients < 10 years old and in teenagers with small lesions (< 30% head involvement), or with good femoral head perfusion, non-weight bearing treatment can be used as a definitive treatment (Figures 2-3).

An experimental study on a piglet model of ischemic osteonecrosis of the femoral head showed decreased femoral head deformity with a non-weight-bearing treatment.<sup>47</sup> In adult FHO, spontaneous resolution was seen in small, asymptomatic lesions.<sup>88</sup> Surgical intervention, however, is indicated in older patients with larger lesions as necrotic bone healing is impaired and slower in these patients with greater likelihood of radiographic progression and femoral head collapse leading to premature osteoarthritis. Since clearly defining the extent of femoral head necrosis is difficult on x-rays in the pre-collapse stage, the use of MRI to stage the disease is recommended. While the role of gadolinium-enhanced MRI is evolving and being defined, it has been shown to have utility in the management of LCPD and should be considered early for treatment planning based on the extent of head involvement.

### Core Decompression and Multiple Small Drilling

Core decompression (CD) was initially reported in early 1970s as a procedure to relieve elevated intraosseous pressure and to stimulate bone healing in adult FHO.<sup>89</sup>



**Figure 3.** A) X-rays of a 9-year-old male with SCD complaining of left hip pain. B) Mid-coronal (left) and sagittal (right) perfusion MRI showing good femoral epiphyseal perfusion except in the subchondral region. The patient was treated nonoperatively with activity and weight-bearing restrictions. C) X-rays obtained 32 months from MRI (age 12).

CD and its variant, multiple small drilling procedure (2-3 mm in diameter), have become commonly used first line of treatment for the pre-collapse stage of adult FHO. Multiple small drilling procedure has the potential advantage of increasing the number and distribution of bone channels for revascularization and invasion of repair cells from the metaphysis while reducing the mechanical instability created by removing a large amount of bone from the femoral head. The procedure produces similar rates of success for Stage I and II adult FHO as the rates reported using conventional CD techniques.<sup>90</sup> The risk of subtrochanteric fracture and inadvertent penetration or blowout of the femoral head associated with a large core technique may also be decreased with multiple small drillings. A recent systemic review of 32 articles reporting on the outcomes of core decompression procedure with or without autologous bone or bone marrow cell transplantation in adult patients with FHO found overall success rate of 65% at a mean follow-up of 54 months.<sup>91</sup> There were significant differences in the outcomes depending on the pre-collapse (Steinberg Stage I or II) vs. post-collapse stage (Stage III) of the

disease and the treatment specifics. In a small randomized prospective study of adult patients with SCD (mean age 26), the hip survival rate (82% vs 86%) and modified Harris hip score were similar in the CD plus physical therapy group (n=17) vs. the physical therapy alone group (n=21) at a mean follow-up of 3 years (range 2 months to 6.7 years). Some limitations of this study included small sample size, inclusion of patients with less than 1-year follow-up, and more patients with femoral head collapse in the CD plus physical therapy group.<sup>92</sup>

The efficacy of CD-type of procedure for pediatric FHO is understudied and remains unclear. The use of core decompression procedure in children raises the concern of iatrogenic injury to the proximal femoral physis causing growth disturbance. It is argued that the application of CD in adolescents with FHO is warranted given less growth potential in the proximal femoral physis at the older age and potential benefit of the procedure based on the results reported in the adult FHO literature.

In a study of 80 pediatric and young adult patients with leukemia or lymphoma and FHO, 35 CDs were performed, primarily in patients who had a collapsed articular surface (6 hips) or a large size lesion (15 hips).<sup>93</sup> CD did not prevent or delay joint surface collapse or arthroplasty. However, because of the retrospective nature of the study and small sample size, the role of CD in preventing or slowing the progression of joint destruction could not be determined definitively.

### **Adjuvant Bone Marrow Aspirate Concentrate (BMAC) Injection**

One important variation to the CD procedure is autologous bone marrow concentrate injection to the center of necrosis.<sup>94</sup> The scientific basis for the adjuvant therapy is that bone marrow is a source of pluripotent mesenchymal stem cells (MSCs) which can differentiate into osteoblasts and enhance bone healing. In adults, it is estimated that the number of MSCs present in the bone marrow is low, ranging from 1 per 10,000 to 1 per 1,000,000 mononuclear cells.<sup>94</sup> Since increasing the number of MSCs for transplantation has been shown to produce

better bone regenerative results, concentration of mononuclear cells in the bone marrow aspirate by cell centrifugation technique to produce a bone marrow aspirate concentrate (BMAC) containing increased concentration of mononuclear cells is advocated.

Studies show that the efficacy of BMAC therapy depends on the quantity of implanted MSCs. In this regard, patients with SCD have significantly favorable MSC availability. Quantitative evaluation of bone marrow stromal cells isolated from SCD patients with osteonecrosis found significantly higher bone marrow mononuclear cells and colony-forming efficiency values from these patients compared to age and sex-matched patients with non-SCD osteonecrosis and normal donors.<sup>95</sup> The MSCs from SCD patients were similar to MSCs from the control groups in terms of their functional properties. In non-leukemic patients with corticosteroid-induced osteonecrosis, lower numbers of MSCs were obtained from the iliac crest.<sup>96</sup> In leukemic patients under chemotherapy, there is further concern regarding the availability and functional effectiveness of these cells to stimulate bone healing. Another theoretical concern is seeding leukemic cells to another site through transplantation. Major limitations of current BMAC therapies for FHO are non-standardized techniques for bone marrow aspiration, processing, and concentrating, and a lack of quality control for the number of MSCs transplanted. Furthermore, no data exists to guide the technical aspects of the procedure to optimize efficacy for adolescent FHO.

### **Technical Note**

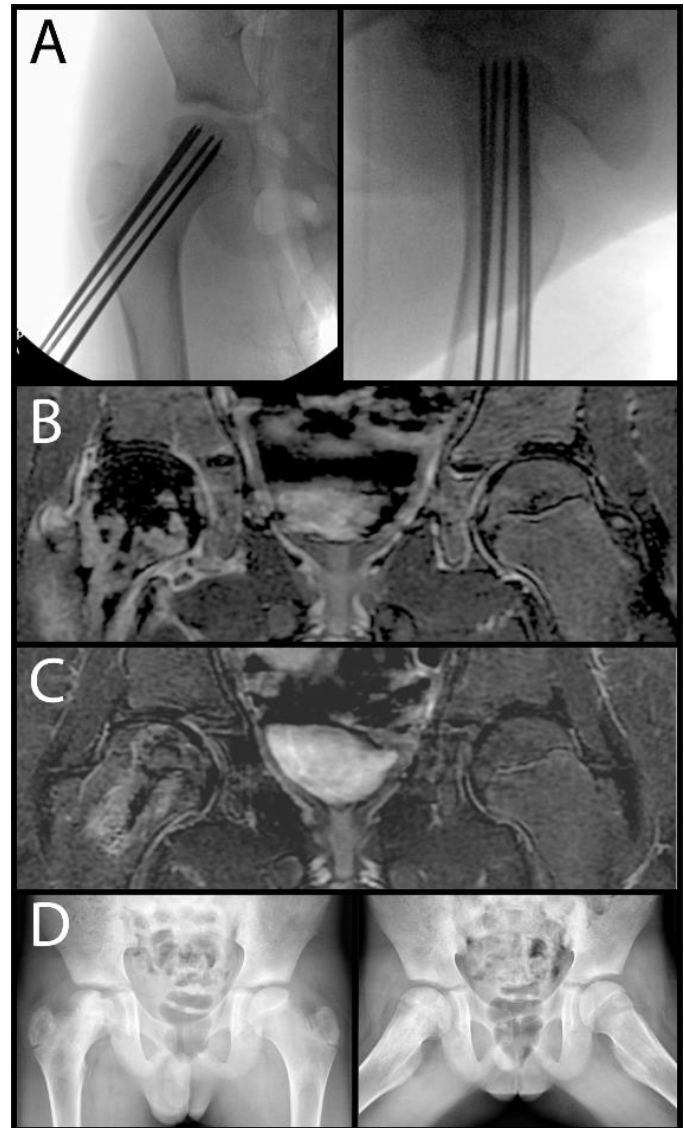
Bone marrow aspiration technique can significantly affect the number of MSC collected from bone marrow due to peripheral blood dilution.<sup>97</sup> Higher number of MSCs are obtained by aspirating smaller volume of bone marrow aspirate (2 ml at a time) at a given needle site to minimize peripheral blood dilution.<sup>98</sup> For adult FHO, average bone marrow aspiration of 150 ml of marrow followed by injection of 20 ml of concentrated mononucleated marrow cells has been reported to produce good results.<sup>99</sup> In other studies, even higher

volumes of marrow aspirate and concentrate were obtained and injected.<sup>100, 101</sup>

### Outcomes of Adjuvant BMAC Therapy

In adult patients with pre-collapse stage osteonecrosis (Stage I or II), injection of BMAC has been shown to stimulate necrotic bone healing and prevent progression of the disease. A systemic review and meta-analysis of 16 published articles of adult patients with various FHO etiologies in the pre-collapse stage revealed that CD plus BMAC therapy resulted in significantly lower hip pain score, higher Harris Hip Score, and lower number of patients progressing to require THA compared to CD alone.<sup>102</sup> In a prospective cohort study, addition of BMAC transplantation to CD improved the outcomes, especially in the patients with SCD, when the procedure was performed before the collapse.<sup>103</sup> In a prospective study of 116 patients (189 hips) treated with CD and BMAC with 5 to 10 years of follow-up, THA was required in nine of the 145 hips when the procedure was done before collapse (Stage I or II) vs. 25 of the 44 hips when the procedure was done after collapse (Stage III or IV). In the study, only two of 64 hips of patients with SCD treated with CD and BMAC injection had a THA. The patients who had a greater number of progenitor cells transplanted in their hips had better outcomes, and the patients with SCD had the highest concentration of mesenchymal progenitor cells and benefited most from the marrow transplantation. As expected, the patients with FHO due to corticosteroid therapy and alcohol use had the lowest numbers of the progenitor cells and were more likely to have a failure of treatment.

In a study of 125 adult patients (mean age 36, range 18-54) with bilateral FHO due to corticosteroids and both hips at the pre-collapse stage, CD with BMAC injection improved the outcome of the disease as compared with CD alone in the same patient.<sup>99</sup> The volume of osteonecrosis was measured with MRI in both hips and the head with smaller osteonecrosis area was treated with CD, whereas the contralateral hip with the larger osteonecrosis area was treated with CD+BMAC. At the av-



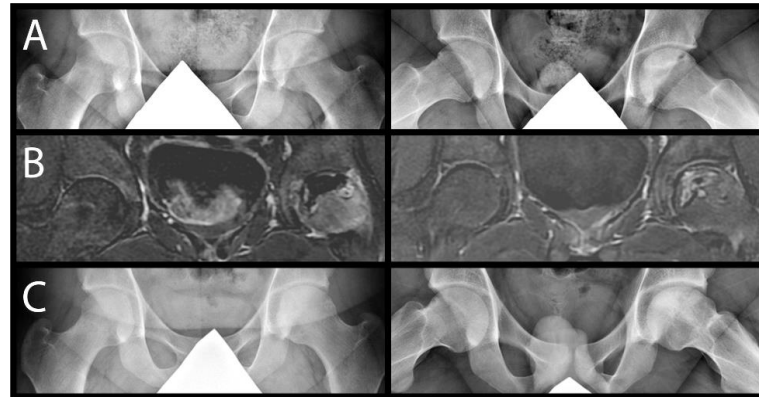
**Figure 4.** A) AP and lateral fluoroscopic views of right proximal femur of an 11-year-old male with SCD treated with multiple epiphyseal drilling using 2.4 mm drillable intraosseous needle and bone marrow aspirate concentrate injection in a pre-collapse stage. B) C) Mid-coronal perfusion MRI before (B) and 6 months after (C) drilling and BMAC treatment showing substantial improvement in the femoral head perfusion. D) X-rays obtained 18 months posttreatment.

erage of 25 years follow-up (range 20 to 30 years), 35 hips (28%) had collapsed in the CD+BMAC group vs. 90 hips (72%) in the CD group. Ninety-five hips (76%) in the CD group underwent THA and 30 hips (24%) in the CD+BMAC group (odds ratio: 10.0; 95% CI: 5.6 to 17.9;  $p < 0.0001$ ).

In comparison to the adult FHO literature, very scant data is available on pediatric FHO. In a retrospective study of 11 patients with SCD and FHO (mean age of 12.7 years at surgery, range 9-18), multiple epiphyseal drilling with autologous bone marrow cell implantation significantly improved pain and hip motion at a mean duration of 25 months (range 12-47 months) with some improvement or no further progression of femoral head deformity.<sup>104</sup> In a case series of 16 patients with SCD and FHO (mean age at diagnosis 13.2 years, range 7-19), all five patients who received core decompression with BMAC and four out of the five patients who received physiotherapy showed no improvement.<sup>105</sup> Most of these patients, however, had a femoral head collapse at diagnosis (Stage III). In our limited experience, multiple epiphyseal drilling with BMAC injection appeared to improve pain and stimulate necrotic bone revascularization and healing in patients with FHO due to SCD, trauma, and corticosteroid therapy (Figures 4-6).

### Femoral or Pelvic Osteotomies

The treatment concept of femoral or pelvic osteotomies is to rotate the necrotic or collapsed segment of the femoral head away from the loading region of the hip joint or to improve the femoral head coverage to decrease the loading stress. When the size of necrotic lesion is large, however, this option is less than ideal. Another important consideration to keep in mind is the potential consequence of a proximal femoral osteotomy on future THA as it can substantially alter the anatomy of the proximal femur. Clinical studies of treatment outcomes after proximal femoral or pelvic osteotomies on pediatric patients with SCD and FHO or corticosteroid induced FHO are very limited and not enough to provide evidence-based treatment guidance. A small retrospective study of 25 hips in 17 patients (mean age at diagnosis 11.4 years; mean follow-up 7.5 years) with SCD and FHO found good radiographic outcomes (Stulberg 1 or 2 hip) in 7/12 hips treated nonoperatively and 5/13 hips treated with femoral varus osteotomy and/or pelvic osteotomy.<sup>106</sup> In the surgical group, two patients required THA and two had poor outcome (Stulberg 5) compared



**Figure 5.** A) X-rays of a 17-year-old male with lymphoma treated with chemotherapy complaining of left hip pain. B) Mid-coronal perfusion MRI obtained before (left image) and 6 months after (right image) multiple epiphyseal drilling and BMAC treatment for FHO involving the anterior third of the femoral head. The follow-up perfusion MRI showed substantial improvement of the hypoperfused region. C) X-rays obtained at 2-year follow-up (age 19).

to one each in the non-surgical group. Those patients who had surgical treatment, however, had more extensive epiphyseal involvement. A case series of seven patients (13 hips) with the mean age of diagnosis at 11.1 years treated with subtrochanteric femoral varus osteotomy or nonoperatively reported similar clinical improvement with surgery.<sup>107</sup> In another retrospective study of pediatric SCD patients treated with either a triple pelvic osteotomy (7 cases), femoral varus osteotomy (2 cases) and a combination of both (2 cases), all patients were considered to be satisfactory at maximum follow-up of 1 to 9.6 years with an objective functional gain.<sup>108</sup>

### Non-vascularized Bone Grafting

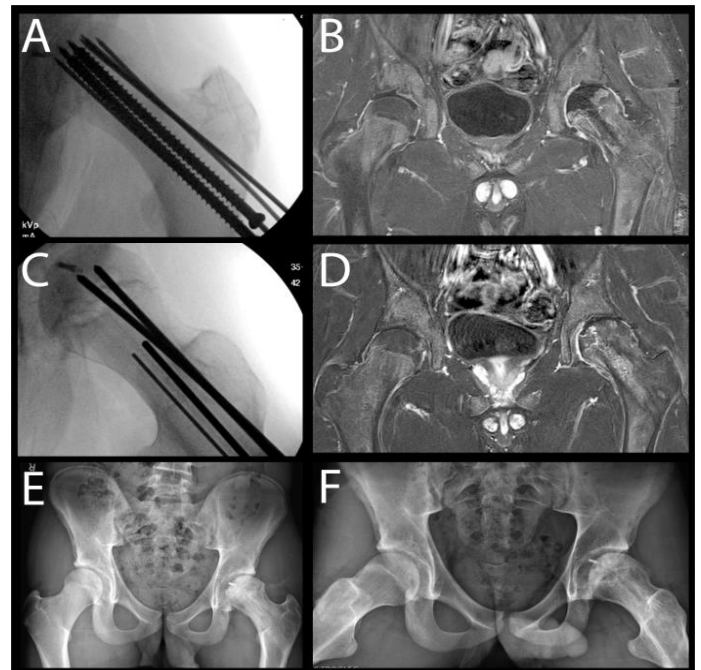
In adult FHO, non-vascularized bone grafting is a treatment option for pre- and post-collapse stages on osteonecrosis. Various bone grafts and techniques have been described, including non-vascularized fibular graft, cortical strut grafts, packing of morselized cancellous bone grafts through a femoral neck window or articular cartilage/subchondral bone trap door.<sup>109</sup> While the short-term results appear to be promising, the number of studies reporting the results of these techniques and the durations of follow-up are limited.



In pediatric FHO, there are only few outcome studies reporting on these treatments. A retrospective study of 13 patients ( $\leq 20$  years old) with FHO related to corticosteroid therapy, SCD, or leukemia treated by thorough decompression of the osteonecrotic zone combined with cancellous bone grafting and stabilization with a nail plate device showed improvement in pain at a mean follow-up of 28 months (range 18-49).<sup>110</sup> Radiologically, all Steinberg Stage II cases (pre-collapse stage), except for one, demonstrated good incorporation of graft without further progression of disease. Seven of the eight patients with Steinberg Stage IIIB hip or higher (post-collapse stage) at the time of procedure had symptomatic and radiologic progression, and deterioration of function. A retrospective study of 13 teenagers (14 hips) treated with a “trapdoor” bone grafting procedure along with containment procedure (femoral osteotomy, acetabular osteotomy, or both) in nine cases (10 hips) for severe FHO with articular surface collapse found a clinical good result in seven cases (8 hips) and a fair result in two.<sup>111</sup> Radiographic evaluation showed six hips with a good result, three hips with a fair result, and one with a poor result. None of these 10 hips has yet required hip fusion or replacement arthroplasty, suggesting that trapdoor bone grafting plus containment can serve as a procedure to delay the need for hip fusion or arthroplasty in teenagers with FHO.

### Vascularized Bone Grafting

Vascularized bone grafting is conceptually appealing as it removes the necrotic bone and replaces it with a vascularized bone, thus, potentially speeding up the healing process. Various anatomical sources and techniques have been described for adult FHO including free vascularized fibular graft (FVFG) and vascularized bone pedicle derived from ileum or greater trochanter and are summarized in a recent review article.<sup>109</sup> The short and intermediate-term outcomes of success range from 70-90% in the literature but most studies had a small number of patients. Treatment considerations are technical difficulties associated with vascular anastomosis, ideal placement of the graft in the femoral head, preparation and bone



**Figure 6.** A) Fluoroscopic images of a 14-year-old male with FHO 6 weeks after traumatic hip dislocation with epiphysiolysis shown in Figure 1. Multiple small drilling was performed followed by bone marrow aspirate concentrate injection. B) At 6 months post-injury, the hardware was removed and perfusion MRI was obtained which demonstrated persistent avascular segment in anteromedial femoral epiphysis, C) Repeat epiphyseal drilling targeting the necrotic anteromedial segment was performed with injection of bone morphogenetic protein-2 infused synthetic bone substitute in prior screw tracks, D) Repeat perfusion MRI at 14 months post-injury demonstrates no evidence of persistent osteonecrosis. E), F) X-rays at 2 years post-injury without significant femoral head collapse.

grafting of adjacent necrotic region, long surgery duration, and potential harvest site morbidity. In patients younger than 12 years, a syndesmotic screw placement is recommended to prevent a progressive ankle valgus deformity after the fibular graft harvest.<sup>112</sup>

A retrospective review of 50 pediatric and adolescent patients (54 hips) who were 18 years of age or younger at the time of free vascularized fibular grafting procedure and who have been at least 2 years follow-up (average 4.3 years) showed progressive collapse in 18 hips (33%) with joint space incongruity in 19 hips (36%). A conversion to THA was performed in seven patients and

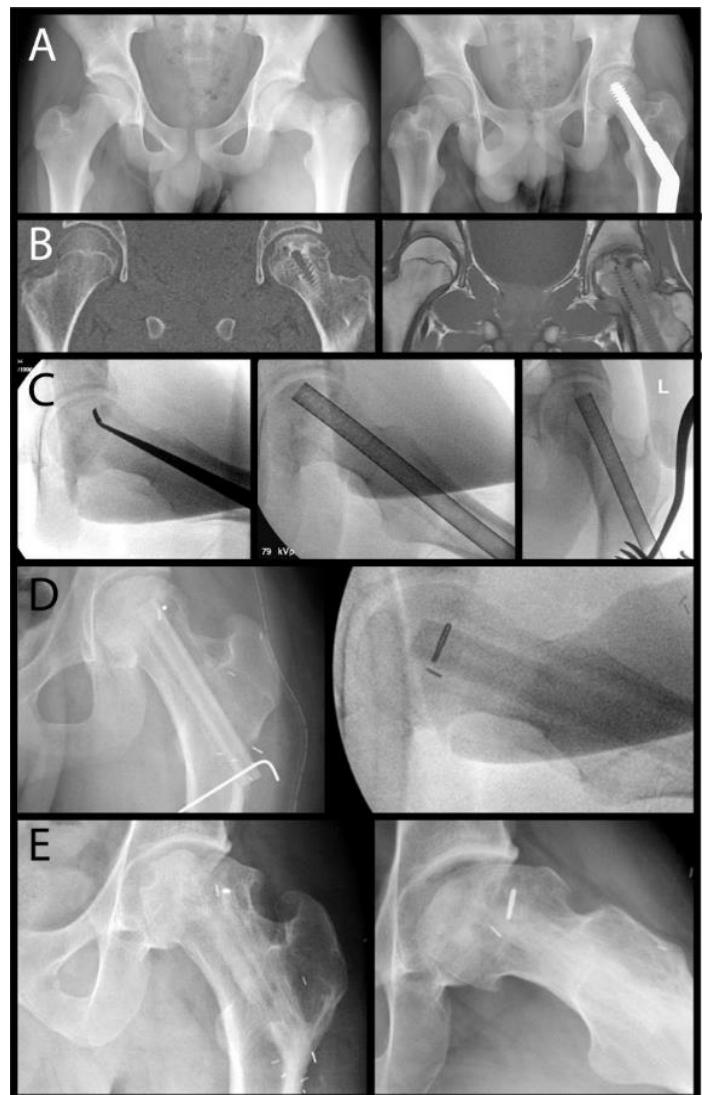


hip fusion in one patient (i.e., 16% conversion to THA or fusion).<sup>112</sup> The average Harris hip scores in patients who did not undergo THA improved from a preoperative average of 55.3 points to 90.2 points at the latest follow-up. The etiology of FHO was trauma in 24 patients, slipped capital femoral epiphysis in 15, corticosteroids in 13, and LCPD in 2. There were no patients with SCD. Most hips (46/54) were in a post-collapse stage based on Marcus classification.<sup>113</sup> While free vascularized fibular graft may not be the long-term solution in the post-collapse stage, it may delay the timing of THA in teenagers with FHO (Figure 7).

### Hip Fusion

Hip fusion is a treatment option for patients with traumatic osteonecrosis if maintenance of active, strenuous lifestyle or work is desired. Hip fusion is not a good treatment option for FHO secondary to SCD and corticosteroid therapy as many of these patients develop bilateral disease. The intermediate and long-term results of hip fusion are generally good, however, low back pain, ipsilateral knee pain, and progressive hip adduction drift are common during follow-up.<sup>114-116</sup> It is recommended that the hip fusion be positioned in 20 degrees flexion and 0 degree abduction, and a limb-length discrepancy should be < 2 cm to minimize the low back pain, quadriceps deficiency, and abnormal gait parameters.<sup>117,118</sup>

In a retrospective study of 28 patients who had a hip fusion at age 10 to 58 (average age 25 years, 14 patients fused before age 20) about 60% of the patients had ipsilateral knee pain (average time to onset, 23 years after arthrodesis) and back pain (average time to onset, 25 years after the operation).<sup>116</sup> These patients had the hip fusion 17 to 50 years previously (average 35 years). Pain in the contralateral hip occurred in approximately 25% of the patients (average time to onset, 20 years after arthrodesis). Only one patient was unemployed due to disabling pain in the back or knee. About 70% of the patients could walk > 1 mile and sit comfortably for at least 2 hours. The patients with hip fusion in abduction more frequently had the ipsilateral knee pain



**Figure 7.** A) X-rays of a 14-year-old male with left femoral neck fracture (left image) treated with a dynamic hip screw device. Patient developed left hip pain and decreased motion 1 year after the fixation. B) Mid-coronal CT and MRI images after the removal of the hip screw showing a mild collapse (1-1.5 mm) of the superior region of the femoral head (Steinberg Stage III) and osteonecrosis involving the antero-central region. C), D) Patient was treated with burring and curettage of necrotic bone followed by autologous iliac crest cancellous bone grafting and free vascularized fibular graft. E) At 10-year follow-up (age 24), the patient was beginning to have symptoms of osteoarthritis with some x-ray findings of osteoarthritis

and the back pain. They also had greater degenerative changes in the ipsilateral knee than the patients whose hip was fused in adduction or in the neutral position. Six patients had undergone THA for the back or the ipsilateral knee, or both. Two patients had a total knee arthroplasty for the ipsilateral knee pain.

### Total Hip Arthroplasty

In older adolescents with FHO for whom nonoperative or other surgical management options have failed, THA is a reliable treatment option for improving pain and function.<sup>119-125</sup> In a series of 88 patients who underwent THA 25 years or younger (approximately half of which were performed for FHO), Clohisy et al.<sup>121</sup> reported improved functional outcomes with a mean Harris Hip score increasing from 42 preoperatively to 83 postoperatively. This study's findings were consistent with other literature in more heterogeneous patient populations.<sup>119, 120, 123-125</sup> Two large registry studies have demonstrated excellent survivorship following THA prior to 21 years of age. In one study of 881 total hip arthroplasties in patients 21 years and younger (performed for multiple etiologies including FHO), the Nordic Arthroplasty Register Association reported survivorship at 10 years of 86%.<sup>122</sup> Similarly, the Australian Orthopaedic Association National Joint Replacement Registry reported on 297 primary THAs in patients under 21 years of age and found a revision rate of 4.5% at 5 years. Although there is limited data on THA for individual etiologies of FHO, a systematic review on THA for SCD highlighted the increased risk of complications within this group. Kenanidis et al.<sup>126</sup> reviewed 15 studies with 971 THAs performed in adults with SCD (mean age at THA between 23.8-37 years) and reported an overall revision rate of 16.8%. Patients with SCD also had an increased perioperative medical

complication rate of 14.3%, primarily sickle cell crises and transfusion reactions. However, all studies within the review also demonstrated functional improvement in patients postoperatively and the authors highlighted the importance of counseling families on this increased risk profile as they consider treatment options.

### Summary

Pediatric FHO affects a wide age range of children. Younger children have a greater potential for healing and remodeling of the necrotic femoral head and tend to have a better outcome compared to adolescents. Pediatric FHO related to SCD and corticosteroid therapy is seen more in adolescents than in younger children and is associated with poorer outcome. Treatment of patients with SCD and corticosteroid induced FHO is complicated by their medical conditions and disease-specific challenges. Treatment approach should be tailored to the age of the patient, the extent of necrosis, and the stage of femoral head deformity. Early diagnosis and treatment prior to femoral head collapse are key to successful femoral head preservation. While surgical treatments, such as multiple epiphyseal drilling with BMAC and other hip preservation procedures, can produce good long-term outcomes in certain patients there is clinical need for large prospective studies to demonstrate the efficacy of these treatments in pediatric FHO. Further, there is urgent need to develop hip preservation procedures to improve the outcome of patients who present with a femoral head collapse.

### Additional Links

“New Paradigms in the Etiology, Pathogenesis, and Treatment of Osteonecrosis,” AAOS 2018

[https://vimeo.com/aaos/review/389605112/a5c0ced60d#comment\\_13674400](https://vimeo.com/aaos/review/389605112/a5c0ced60d#comment_13674400)

## References

1. Canale ST, Bourland WL. Fracture of the neck and intertrochanteric region of the femur in children. *J Bone Joint Surg Am.* 1977 Jun;59(4):431-43.
2. Ratliff AH. Fractures of the neck of the femur in children. *J Bone Joint Surg Br.* 1962 Aug;44-B:528-42.
3. Shrader MW, Jacofsky DJ, Stans AA, Shaughnessy WJ, Haidukewych GJ. Femoral neck fractures in pediatric patients: 30 years experience at a level 1 trauma center. *Clin Orthop Relat Res.* 2007 Jan;454:169-73.
4. Leung PC, Lam SF. Long-term follow-up of children with femoral neck fractures. *J Bone Joint Surg Br.* 1986 Aug;68(4):537-40.
5. Bali K, Sudesh P, Patel S, Kumar V, Saini U, Dhillon MS. Pediatric femoral neck fractures: our 10 years of experience. *Clin Orthop Surg.* 2011 Dec;3(4):302-8.
6. Song KS. Displaced fracture of the femoral neck in children: open versus closed reduction. *J Bone Joint Surg Br.* 2010 Aug;92(8):1148-51.
7. Forlin E, Guille JT, Kumar SJ, Rhee KJ. Complications associated with fracture of the neck of the femur in children. *J Pediatr Orthop.* 1992 Jul-Aug;12(4):503-9.
8. Stone JD, Hill MK, Pan Z, Novais EN. Open Reduction of Pediatric Femoral Neck Fractures Reduces Osteonecrosis Risk. *Orthopedics.* 2015 Nov;38(11):e983-90.
9. Moon ES, Mehlman CT. Risk factors for avascular necrosis after femoral neck fractures in children: 25 Cincinnati cases and meta-analysis of 360 cases. *J Orthop Trauma.* 2006 May;20(5):323-9.
10. Spence D, DiMauro JP, Miller PE, Glotzbecker MP, Hedequist DJ, Shore BJ. Osteonecrosis After Femoral Neck Fractures in Children and Adolescents: Analysis of Risk Factors. *J Pediatr Orthop.* 2016 Mar;36(2):111-6.
11. Yeranorian M, Horneff JG, Baldwin K, Hosalkar HS. Factors affecting the outcome of fractures of the femoral neck in children and adolescents: a systematic review. *Bone Joint J.* 2013 Jan;95-B(1):135-42.
12. Colonna PC. Fracture of the Neck of the Femur in Childhood: A Report of Six Cases. *Ann Surg.* 1928 Nov;88(5):902-7.
13. Delbet M. Fractures du col de femur. *Bull Mem Soc Chir.* 1907;35:387-9.
14. Offierski CM. Traumatic dislocation of the hip in children. *J Bone Joint Surg Br.* 1981 Aug;63-B(2):194-7.
15. Mehlman CT, Hubbard GW, Crawford AH, Roy DR, Wall EJ. Traumatic hip dislocation in children. Long-term followup of 42 patients. *Clin Orthop Relat Res.* 2000 Jul(376):68-79.
16. Vialle R, Odent T, Pannier S, Pauthier F, Laumonier F, Glorion C. Traumatic hip dislocation in childhood. *J Pediatr Orthop.* 2005 Mar-Apr;25(2):138-44.
17. Odent T, Glorion C, Pannier S, Bronfen C, Langlais J, Pouliquen JC. Traumatic dislocation of the hip with separation of the capital epiphysis: 5 adolescent patients with 3-9 years of follow-up. *Acta Orthop Scand.* 2003 Feb;74(1):49-52.
18. Herrera-Soto JA, Price CT, Reuss BL, Riley P, Kasser JR, Beaty JH. Proximal femoral epiphysiolysis during reduction of hip dislocation in adolescents. *J Pediatr Orthop.* 2006 May-Jun;26(3):371-4.
19. Vanderhave KL, Perkins CA, Scannell B, Brighton BK. Orthopaedic Manifestations of Sickle Cell Disease. *J Am Acad Orthop Surg.* 2018 Feb 1;26(3):94-101.
20. Milner PF, Kraus AP, Sebes JL, et al. Sickle cell disease as a cause of osteonecrosis of the femoral head. *N Engl J Med.* 1991 Nov 21;325(21):1476-81.
21. Adesina O, Brunson A, Keegan THM, Wun T. Osteonecrosis of the femoral head in sickle cell disease: prevalence, comorbidities, and surgical outcomes in California. *Blood Adv.* 2017 Jul 11;1(16):1287-95.
22. Powell C, Chang C, Naguwa SM, Cheema G, Gershwin ME. Steroid induced osteonecrosis: An analysis of steroid dosing risk. *Autoimmun Rev.* 2010 Sep;9(11):721-43.
23. Nakamura J, Saisu T, Yamashita K, Suzuki C, Kamegaya M, Takahashi K. Age at time of corticosteroid administration is a risk factor for osteonecrosis in pediatric patients with systemic lupus erythematosus: a prospective magnetic resonance imaging study. *Arthritis Rheum.* 2010 Feb;62(2):609-15.
24. Burger B, Beier R, Zimmermann M, Beck JD, Reiter A, Schrappe M. Osteonecrosis: a treatment related toxicity in childhood acute lymphoblastic leukemia (ALL)--experiences from trial ALL-BFM 95. *Pediatr Blood Cancer.* 2005 Mar;44(3):220-5.
25. Nakamura J, Harada Y, Oinuma K, Iida S, Kishida S, Takahashi K. Spontaneous repair of asymptomatic osteonecrosis associated with corticosteroid therapy in

- systemic lupus erythematosus: 10-year minimum follow-up with MRI. *Lupus*. 2010 Oct;19(11):1307-14.
26. Mont MA, Zywił MG, Marker DR, McGrath MS, Delanois RE. The natural history of untreated asymptomatic osteonecrosis of the femoral head: a systematic literature review. *J Bone Joint Surg Am*. 2010 Sep 15;92(12):2165-70.
27. Kunstreich M, Kummer S, Laws HJ, Borkhardt A, Kuhlen M. Osteonecrosis in children with acute lymphoblastic leukemia. *Haematologica*. 2016 Nov;101(11):1295-305.
28. Kawedia JD, Kaste SC, Pei D, et al. Pharmacokinetic, pharmacodynamic, and pharmacogenetic determinants of osteonecrosis in children with acute lymphoblastic leukemia. *Blood*. 2011 Feb 24;117(8):2340-7; quiz 556.
29. Niinimäki T, Harila-Saari A, Niinimäki R. The diagnosis and classification of osteonecrosis in patients with childhood leukemia. *Pediatr Blood Cancer*. 2015 Feb;62(2):198-203.
30. te Winkel ML, Pieters R, Hop WC, et al. Prospective study on incidence, risk factors, and long-term outcome of osteonecrosis in pediatric acute lymphoblastic leukemia. *J Clin Oncol*. 2011 Nov 1;29(31):4143-50.
31. Elmantaser M, Stewart G, Young D, Duncan R, Gibson B, Ahmed SF. Skeletal morbidity in children receiving chemotherapy for acute lymphoblastic leukaemia. *Arch Dis Child*. 2010 Oct;95(10):805-9.
32. Mattano LA, Jr., Devidas M, Nachman JB, et al. Effect of alternate-week versus continuous dexamethasone scheduling on the risk of osteonecrosis in paediatric patients with acute lymphoblastic leukaemia: results from the CCG-1961 randomised cohort trial. *Lancet Oncol*. 2012 Sep;13(9):906-15.
33. Kadan-Lottick NS, Dinu I, Wasilewski-Masker K, et al. Osteonecrosis in adult survivors of childhood cancer: a report from the childhood cancer survivor study. *J Clin Oncol*. 2008 Jun 20;26(18):3038-45.
34. Chung SM. The arterial supply of the developing proximal end of the human femur. *J Bone Joint Surg Am*. 1976 Oct;58(7):961-70.
35. Trueta J. The normal vascular anatomy of the human femoral head during growth. *J Bone Joint Surg Br*. 1957 May;39-B(2):358-94.
36. Morris WZ, Liu RW, Chen E, Kim HK. Analysis of Trabecular Microstructure and Vascular Distribution of Capital Femoral Epiphysis Relevant to Legg-Calve-Perthes Disease. *J Orthop Res*. 2019 Aug;37(8):1784-9.
37. Yawn BP, Buchanan GR, Afenyi-Annan AN, et al. Management of sickle cell disease: summary of the 2014 evidence-based report by expert panel members. *JAMA*. 2014 Sep 10;312(10):1033-48.
38. Aguilar C, Vichinsky E, Neumayr L. Bone and joint disease in sickle cell disease. *Hematol Oncol Clin North Am*. 2005 Oct;19(5):929-41, viii.
39. Kerachian MA, Seguin C, Harvey EJ. Glucocorticoids in osteonecrosis of the femoral head: a new understanding of the mechanisms of action. *J Steroid Biochem Mol Biol*. 2009 Apr;114(3-5):121-8.
40. Weinstein RS, Jilka RL, Parfitt AM, Manolagas SC. Inhibition of osteoblastogenesis and promotion of apoptosis of osteoblasts and osteocytes by glucocorticoids. Potential mechanisms of their deleterious effects on bone. *J Clin Invest*. 1998 Jul 15;102(2):274-82.
41. Weinstein RS. Glucocorticoid-induced osteoporosis and osteonecrosis. *Endocrinol Metab Clin North Am*. 2012 Sep;41(3):595-611.
42. Jones JP, Jr. Intravascular coagulation and osteonecrosis. *Clin Orthop Relat Res*. 1992 Apr(277):41-53.
43. Vogt CJ, Schmid-Schonbein GW. Microvascular endothelial cell death and rarefaction in the glucocorticoid-induced hypertensive rat. *Microcirculation*. 2001 Apr;8(2):129-39.
44. Kim HK, Herring JA. Pathophysiology, classifications, and natural history of Perthes disease. *Orthop Clin North Am*. 2011 Jul;42(3):285-95, v.
45. Aruwajoye OO, Patel MK, Allen MR, Burr DB, Aswath PB, Kim HK. Microcrack density and nanomechanical properties in the subchondral region of the immature piglet femoral head following ischemic osteonecrosis. *Bone*. 2013 Feb;52(2):632-9.
46. Wang C, Meng H, Wang Y, et al. Analysis of early stage osteonecrosis of the human femoral head and the mechanism of femoral head collapse. *Int J Biol Sci*. 2018;14(2):156-64.
47. Kim HK, Aruwajoye O, Stetler J, Stall A. Effects of non-weight-bearing on the immature femoral head following ischemic osteonecrosis: an experimental investigation in immature pigs. *J Bone Joint Surg Am*. 2012 Dec 19;94(24):2228-37.
48. Morsy HA. Complications of fracture of the neck of the femur in children. A long-term follow-up study. *Injury*. 2001 Jan;32(1):45-51.

49. Davison BL, Weinstein SL. Hip fractures in children: a long-term follow-up study. *J Pediatr Orthop.* 1992 May-Jun;12(3):355-8.
50. Hernigou P, Galacteros F, Bachir D, Goutallier D. Deformities of the hip in adults who have sickle-cell disease and had avascular necrosis in childhood. A natural history of fifty-two patients. *J Bone Joint Surg Am.* 1991 Jan;73(1):81-92.
51. Hernigou P, Bachir D, Galacteros F. The natural history of symptomatic osteonecrosis in adults with sickle-cell disease. *J Bone Joint Surg Am.* 2003 Mar;85(3):500-4.
52. Kaste SC, Pei D, Cheng C, et al. Utility of early screening magnetic resonance imaging for extensive hip osteonecrosis in pediatric patients treated with glucocorticoids. *J Clin Oncol.* 2015 Feb 20;33(6):610-5.
53. Mattano LA, Jr., Sather HN, Trigg ME, Nachman JB. Osteonecrosis as a complication of treating acute lymphoblastic leukemia in children: a report from the Children's Cancer Group. *J Clin Oncol.* 2000 Sep 15;18(18):3262-72.
54. Ness KK, Hudson MM, Ginsberg JP, et al. Physical performance limitations in the Childhood Cancer Survivor Study cohort. *J Clin Oncol.* 2009 May 10;27(14):2382-9.
55. DeFeo BM, Kaste SC, Li Z, et al. Long-Term Functional Outcomes Among Childhood Survivors of Cancer Who Have a History of Osteonecrosis. *Phys Ther.* 2020 Mar 10;100(3):509-22.
56. Mayer SW, Mayer BK, Mack Aldridge J, Urbaniak JR, Fitch RD, Lark RK. Osteonecrosis of the femoral head in childhood malignancy. *J Child Orthop.* 2013 Mar;7(2):111-6.
57. Bond J, Adams S, Richards S, Vora A, Mitchell C, Goulden N. Polymorphism in the PAI-1 (SERPINE1) gene and the risk of osteonecrosis in children with acute lymphoblastic leukemia. *Blood.* 2011 Sep 1;118(9):2632-3.
58. French D, Hamilton LH, Mattano LA, Jr., et al. A PAI-1 (SERPINE1) polymorphism predicts osteonecrosis in children with acute lymphoblastic leukemia: a report from the Children's Oncology Group. *Blood.* 2008 May 1;111(9):4496-9.
59. Karol SE, Yang W, Van Driest SL, et al. Genetics of glucocorticoid-associated osteonecrosis in children with acute lymphoblastic leukemia. *Blood.* 2015 Oct 8;126(15):1770-6.
60. Worrall D, Smith-Whitley K, Wells L. Hemoglobin to Hematocrit Ratio: The Strongest Predictor of Femoral Head Osteonecrosis in Children With Sickle Cell Disease. *J Pediatr Orthop.* 2016 Mar;36(2):139-44.
61. Sultan AA, Mohamed N, Samuel LT, et al. Classification systems of hip osteonecrosis: an updated review. *Int Orthop.* 2019 May;43(5):1089-95.
62. Yoon BH, Mont MA, Koo KH, et al. The 2019 Revised Version of Association Research Circulation Osseous Staging System of Osteonecrosis of the Femoral Head. *J Arthroplasty.* 2020 Apr;35(4):933-40.
63. Ha AS, Wells L, Jaramillo D. Importance of sagittal MR imaging in nontraumatic femoral head osteonecrosis in children. *Pediatr Radiol.* 2008 Nov;38(11):1195-200.
64. Du J, Lu A, Dempsey M, Herring JA, Kim HK. MR perfusion index as a quantitative method of evaluating epiphyseal perfusion in Legg-Calve-Perthes disease and correlation with short-term radiographic outcome: a preliminary study. *J Pediatr Orthop.* 2013 Oct-Nov;33(7):707-13.
65. Kim HK, Kaste S, Dempsey M, Wilkes D. A comparison of non-contrast and contrast-enhanced MRI in the initial stage of Legg-Calve-Perthes disease. *Pediatr Radiol.* 2013 Sep;43(9):1166-73.
66. Hu LB, Huang ZG, Wei HY, Wang W, Ren A, Xu YY. Osteonecrosis of the femoral head: using CT, MRI and gross specimen to characterize the location, shape and size of the lesion. *Br J Radiol.* 2015 Feb;88(1046):20140508.
67. Yeh LR, Chen CK, Huang YL, Pan HB, Yang CF. Diagnostic performance of MR imaging in the assessment of subchondral fractures in avascular necrosis of the femoral head. *Skeletal Radiol.* 2009 Jun;38(6):559-64.
68. Schwaiger BJ, Schneider C, Kronthaler S, et al. CT-like images based on T1 spoiled gradient-echo and ultra-short echo time MRI sequences for the assessment of vertebral fractures and degenerative bone changes of the spine. *Eur Radiol.* 2021 Jan 14.
69. Kaste SC, DeFeo BM, Neel MD, Weiss KS, Fernandez-Pineda I, Ness KK. Osteonecrosis of the Shoulders in Pediatric Patients Treated for Leukemia or Lymphoma: Single-Institutional Experience. *J Pediatr Orthop.* 2019 Feb;39(2):104-10.
70. Te Winkel ML, Pieters R, Wind EJ, Bessems JH, van den Heuvel-Eibrink MM. Management and treatment of osteonecrosis in children and adolescents with acute lymphoblastic leukemia. *Haematologica.* 2014 Mar;99(3):430-6.
71. Jones LC, Kaste SC, Karol SE, et al. Team approach: Management of osteonecrosis in children with acute

- lymphoblastic leukemia. *Pediatr Blood Cancer*. 2020 Nov;67(11):e28509.
72. Heneghan MB, Rheingold SR, Li Y, et al. Treatment of Osteonecrosis in Children and Adolescents With Acute Lymphoblastic Leukemia. *Clin Lymphoma Myeloma Leuk*. 2016 Apr;16(4):223-9 e2.
73. Howard J, Malfroy M, Llewelyn C, et al. The Transfusion Alternatives Preoperatively in Sickle Cell Disease (TAPS) study: a randomised, controlled, multicentre clinical trial. *Lancet*. 2013 Mar 16;381(9870):930-8.
74. Li D, Yang Z, Wei Z, Kang P. Efficacy of bisphosphonates in the treatment of femoral head osteonecrosis: A PRISMA-compliant meta-analysis of animal studies and clinical trials. *Sci Rep*. 2018 Jan 23;8(1):1450.
75. Young ML, Little DG, Kim HK. Evidence for using bisphosphonate to treat Legg-Calve-Perthes disease. *Clin Orthop Relat Res*. 2012 Sep;470(9):2462-75.
76. Aya-ay J, Athavale S, Morgan-Bagley S, Bian H, Bauss F, Kim HK. Retention, distribution, and effects of intraosseously administered ibandronate in the infarcted femoral head. *J Bone Miner Res*. 2007 Jan;22(1):93-100.
77. Kim HK, Sanders M, Athavale S, Bian H, Bauss F. Local bioavailability and distribution of systemically (parenterally) administered ibandronate in the infarcted femoral head. *Bone*. 2006 Jul;39(1):205-12.
78. Aruwajoye OO, Aswath PB, Kim HKW. Material properties of bone in the femoral head treated with ibandronate and BMP-2 following ischemic osteonecrosis. *J Orthop Res*. 2017 Jul;35(7):1453-60.
79. Kotecha RS, Powers N, Lee SJ, Murray KJ, Carter T, Cole C. Use of bisphosphonates for the treatment of osteonecrosis as a complication of therapy for childhood acute lymphoblastic leukaemia (ALL). *Pediatr Blood Cancer*. 2010 Jul 1;54(7):934-40.
80. Leblicq C, Laverdiere C, Decarie JC, et al. Effectiveness of pamidronate as treatment of symptomatic osteonecrosis occurring in children treated for acute lymphoblastic leukemia. *Pediatr Blood Cancer*. 2013 May;60(5):741-7.
81. McQuade M, Houghton K. Use of bisphosphonates in a case of Perthes disease. *Orthop Nurs*. 2005 Nov-Dec;24(6):393-8.
82. Nguyen T, Zacharin MR. Pamidronate treatment of steroid associated osteonecrosis in young patients treated for acute lymphoblastic leukaemia--two-year outcomes. *J Pediatr Endocrinol Metab*. 2006 Feb;19(2):161-7.
83. Ramachandran M, Ward K, Brown RR, Munns CF, Cowell CT, Little DG. Intravenous bisphosphonate therapy for traumatic osteonecrosis of the femoral head in adolescents. *J Bone Joint Surg Am*. 2007 Aug;89(8):1727-34.
84. Brawley OW, Cornelius LJ, Edwards LR, et al. National Institutes of Health Consensus Development Conference statement: hydroxyurea treatment for sickle cell disease. *Ann Intern Med*. 2008 Jun 17;148(12):932-8.
85. Charache S, Terrin ML, Moore RD, et al. Effect of hydroxyurea on the frequency of painful crises in sickle cell anemia. Investigators of the Multicenter Study of Hydroxyurea in Sickle Cell Anemia. *N Engl J Med*. 1995 May 18;332(20):1317-22.
86. Lemonne N, Mockesch B, Charlot K, et al. Effects of hydroxyurea on blood rheology in sickle cell anemia: A two-years follow-up study. *Clin Hemorheol Microcirc*. 2017;67(2):141-8.
87. Zimmerman SA, Schultz WH, Davis JS, et al. Sustained long-term hematologic efficacy of hydroxyurea at maximum tolerated dose in children with sickle cell disease. *Blood*. 2004 Mar 15;103(6):2039-45.
88. Cheng EY, Thongtrangan I, Laorr A, Saleh KJ. Spontaneous resolution of osteonecrosis of the femoral head. *J Bone Joint Surg Am*. 2004 Dec;86(12):2594-9.
89. Arlet J, Ficat P, Lartigue G, Tran MA. [Clinical research on intraosseous pressure in the upper femoral metaphysis and epiphysis in humans. Application to the diagnosis of ischemia and necrosis]. *Rev Rhum Mal Osteoartic*. 1972 Nov;39(11):717-23.
90. Marker DR, Seyler TM, Ulrich SD, Srivastava S, Mont MA. Do modern techniques improve core decompression outcomes for hip osteonecrosis? *Clin Orthop Relat Res*. 2008 May;466(5):1093-103.
91. Hua KC, Yang XG, Feng JT, et al. The efficacy and safety of core decompression for the treatment of femoral head necrosis: a systematic review and meta-analysis. *J Orthop Surg Res*. 2019 Sep 11;14(1):306.
92. Neumayr LD, Aguilar C, Earles AN, et al. Physical therapy alone compared with core decompression and physical therapy for femoral head osteonecrosis in sickle cell disease. Results of a multicenter study at a mean of three years after treatment. *J Bone Joint Surg Am*. 2006 Dec;88(12):2573-82.

93. Karimova EJ, Rai SN, Howard SC, et al. Femoral head osteonecrosis in pediatric and young adult patients with leukemia or lymphoma. *J Clin Oncol*. 2007 Apr 20;25(12):1525-31.
94. Hernigou P, Guerin G, Homma Y, et al. History of concentrated or expanded mesenchymal stem cells for hip osteonecrosis: is there a target number for osteonecrosis repair? *Int Orthop*. 2018 Jul;42(7):1739-45.
95. Lebouvier A, Poignard A, Coquelin-Salsac L, et al. Autologous bone marrow stromal cells are promising candidates for cell therapy approaches to treat bone degeneration in sickle cell disease. *Stem Cell Res*. 2015 Nov;15(3):584-94.
96. Hernigou P, Beaujean F. Abnormalities in the bone marrow of the iliac crest in patients who have osteonecrosis secondary to corticosteroid therapy or alcohol abuse. *J Bone Joint Surg Am*. 1997 Jul;79(7):1047-53.
97. Hernigou P, Flouzat-Lachaniette CH, Delambre J, et al. Osteonecrosis repair with bone marrow cell therapies: state of the clinical art. *Bone*. 2015 Jan;70:102-9.
98. Piuze NS, Mantripragada VP, Sumski A, Selvam S, Boehm C, Muschler GF. Bone Marrow-Derived Cellular Therapies in Orthopaedics: Part I: Recommendations for Bone Marrow Aspiration Technique and Safety. *J Bone Joint Surg Am*. 2018 Nov;6(11):e4.
99. Hernigou P, Dubory A, Homma Y, et al. Cell therapy versus simultaneous contralateral decompression in symptomatic corticosteroid osteonecrosis: a thirty year follow-up prospective randomized study of one hundred and twenty five adult patients. *Int Orthop*. 2018 Jul;42(7):1639-49.
100. Gangji V, Hauzeur JP, Matos C, De Maertelaer V, Toungouz M, Lambermont M. Treatment of osteonecrosis of the femoral head with implantation of autologous bone-marrow cells. A pilot study. *J Bone Joint Surg Am*. 2004 Jun;86(6):1153-60.
101. Gangji V, De Maertelaer V, Hauzeur JP. Autologous bone marrow cell implantation in the treatment of non-traumatic osteonecrosis of the femoral head: Five year follow-up of a prospective controlled study. *Bone*. 2011 Nov;49(5):1005-9.
102. Zhang C, Fang X, Huang Z, Li W, Zhang W, Lee GC. Addition of Bone Marrow Stem Cells Therapy Achieves Better Clinical Outcomes and Lower Rates of Disease Progression Compared With Core Decompression Alone for Early Stage Osteonecrosis of the Femoral Head: A Systematic Review and Meta-Analysis. *J Am Acad Orthop Surg*. 2020 Dec 1;28(23):973-9.
103. Hernigou P, Beaujean F. Treatment of osteonecrosis with autologous bone marrow grafting. *Clin Orthop Relat Res*. 2002 Dec(405):14-23.
104. Novais EN, Sankar WN, Wells L, Carry PM, Kim YJ. Preliminary Results of Multiple Epiphyseal Drilling and Autologous Bone Marrow Implantation for Osteonecrosis of the Femoral Head Secondary to Sickle Cell Disease in Children. *J Pediatr Orthop*. 2015 Dec;35(8):810-5.
105. Itzep NP, Jadhav SP, Kanne CK, Sheehan VA. Spontaneous healing of avascular necrosis of the femoral head in sickle cell disease. *Am J Hematol*. 2019 Jun;94(6):E160-E2.
106. Mallet C, Abitan A, Vidal C, et al. Management of osteonecrosis of the femoral head in children with sickle cell disease: results of conservative and operative treatments at skeletal maturity. *J Child Orthop*. 2018 Feb 1;12(1):47-54.
107. Athanassiou-Metaxa M, Kirkos J, Koussi A, Hatzipantelis E, Tsatra I, Economou M. Avascular necrosis of the femoral head among children and adolescents with sickle cell disease in Greece. *Haematologica*. 2002 Jul;87(7):771-2.
108. Gatin L, Rogier de Mare A, Mary P, Vialle R, Damsin JP. Osteonecrosis of the Femoral Head: A Proposed New Treatment in Homozygous Sickle Cell Disease. *Hemoglobin*. 2016;40(1):1-9.
109. Mont MA, Salem HS, Piuze NS, Goodman SB, Jones LC. Nontraumatic Osteonecrosis of the Femoral Head: Where Do We Stand Today?: A 5-Year Update. *J Bone Joint Surg Am*. 2020 Jun 17;102(12):1084-99.
110. Wells L, Hosalkar HS, Crawford EA, Agrawal N, Goebel J, Dormans JP. Thorough debridement under endoscopic visualization with bone grafting and stabilization for femoral head osteonecrosis in children. *J Pediatr Orthop*. 2009 Jun;29(4):319-26.
111. Ko JY, Meyers MH, Wenger DR. "Trapdoor" procedure for osteonecrosis with segmental collapse of the femoral head in teenagers. *J Pediatr Orthop*. 1995 Jan-Feb;15(1):7-15.
112. Dean GS, Kime RC, Fitch RD, Gunneson E, Urbaniak JR. Treatment of osteonecrosis in the hip of pediatric patients by free vascularized fibular graft. *Clin Orthop Relat Res*. 2001 May(386):106-13.

113. Marcus ND, Enneking WF, Massam RA. The silent hip in idiopathic aseptic necrosis. Treatment by bone-grafting. *J Bone Joint Surg Am.* 1973 Oct;55(7):1351-66.
114. Fulkerson JP. Arthrodesis for disabling hip pain in children and adolescents. *Clin Orthop Relat Res.* 1977 Oct(128):296-302.
115. Sponseller PD, McBeath AA, Perpich M. Hip arthrodesis in young patients. A long-term follow-up study. *J Bone Joint Surg Am.* 1984 Jul;66(6):853-9.
116. Callaghan JJ, Brand RA, Pedersen DR. Hip arthrodesis. A long-term follow-up. *J Bone Joint Surg Am.* 1985 Dec;67(9):1328-35.
117. Benaroch TE, Richards BS, Haideri N, Smith C. Intermediate follow-up of a simple method of hip arthrodesis in adolescent patients. *J Pediatr Orthop.* 1996 Jan-Feb;16(1):30-6.
118. Bittersohl B, Zaps D, Bomar JD, Hosalkar HS. Hip arthrodesis in the pediatric population: where do we stand? *Orthop Rev (Pavia).* 2011;3(2):e13.
119. Bernhard ME, Barnes CL, DeFeo BM, et al. Total Hip Arthroplasty in Adolescents and Young Adults for Management of Advanced Corticosteroid-Induced Osteonecrosis Secondary to Treatment for Hematologic Malignancies. *J Arthroplasty.* 2021 Apr;36(4):1352-60.
120. Finkbone PR, Severson EP, Cabanela ME, Trousdale RT. Ceramic-on-ceramic total hip arthroplasty in patients younger than 20 years. *J Arthroplasty.* 2012 Feb;27(2):213-9.
121. Clohisy JC, Oryhon JM, Seyler TM, et al. Function and fixation of total hip arthroplasty in patients 25 years of age or younger. *Clin Orthop Relat Res.* 2010 Dec;468(12):3207-13.
122. Halvorsen V, Fenstad AM, Engesaeter LB, et al. Outcome of 881 total hip arthroplasties in 747 patients 21 years or younger: data from the Nordic Arthroplasty Register Association (NARA) 1995-2016. *Acta Orthop.* 2019 Aug;90(4):331-7.
123. Sedrakyan A, Romero L, Graves S, et al. Survivorship of hip and knee implants in pediatric and young adult populations: analysis of registry and published data. *J Bone Joint Surg Am.* 2014 Dec 17;96 Suppl 1:73-8.
124. Busch V, Klarenbeek R, Slooff T, Schreurs BW, Gardeniers J. Cemented hip designs are a reasonable option in young patients. *Clin Orthop Relat Res.* 2010 Dec;468(12):3214-20.
125. Buddhdev PK, Vanhegan IS, Khan T, Hashemi-Nejad A. Early to medium-term outcomes of uncemented ceramic-bearing total hip arthroplasty in teenagers for paediatric hip conditions. *Bone Joint J.* 2020 Nov;102-B(11):1491-6.
126. Kenanidis E, Kapriniotis K, Anagnostis P, Potoupnis M, Christofilopoulos P, Tsiridis E. Total hip arthroplasty in sickle cell disease: a systematic review. *EFORT Open Rev.* 2020 Mar;5(3):180-8.