Patellar Sleeve Fracture: Open Reduction and Internal Fixation

Andrew G. Georgiadis, MD[1,2] and Shea M. Comadoll, MD[1,2]

[1]Department of Orthopaedic Surgery, Gillette Children's Specialty Healthcare, St. Paul, MN; [2]Department of Orthopaedic Surgery University of Minnesota, Minneapolis, MN

Abstract:
Patellar sleeve fractures are a rare injury comprising less than 1% of all pediatric fractures. They are characterized by a sleeve of articular cartilage pulled away from the osseous patella. The most common pattern is an osteochondral fracture at the inferior patellar pole, but lateral or medial based injuries are also reported. Multiple fixation methods are described depending on fracture pattern, osseous fragment size, and surgeon preference. The specific technique of patellar sleeve fixation utilizing transosseous suture placement is described and illustrated with an accompanying video.

Key Concepts:

- Patellar sleeve injuries are infrequent and can go unrecognized if osseous fragments are absent or small.
- Multiple fixation methods exist which may be utilized based on surgeon preference and size of osseous fragments.
- Early recognition and treatment are key for optimizing outcomes regardless of operative technique utilized.

Introduction

Patellar sleeve injuries comprise 1% of all pediatric fractures[1] but represent the most common patellar fracture pattern in children.[2] These are unique to the pediatric population and occur when a sudden eccentric and longitudinal force avulses a sleeve of cartilage from the inferior pole of the osseous patella.[3] The avulsed cartilage can also have attached bony fragments.

Diagnosis can be difficult because of the unique ossification pattern of the patella. Multiple ossicles begin to appear during early childhood, progressively coalescing and ossifying centrifugally, and these can remain visible even in a mature patella.[4,5] It can be challenging to radiographically differentiate these ossicles from a true fracture, although most accessory patellar ossicles are superior, whereas patellar sleeve fractures almost always occur at the inferior pole. This, in combination with clinical history, should ease the identification of patellar sleeve injuries, which are best evaluated on a lateral radiograph of the knee (Figure 1). MRI can characterize fragment morphology (Figure 2) or clinch the diagnosis in cases where plain radiographs are equivocal (Figure 3). The patella's mechanical role is to act as a fulcrum for the quadriceps musculature. The mechanism of fracture is as follows: the immature patella and the direct attachment of cartilage to bone is the "weak point" during a strong eccentric contraction of the quadriceps in knee flexion.[6]

Copyright @ 2021 JPOSNA

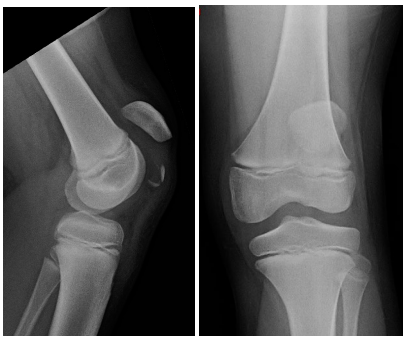

Figure 1. *AP and lateral projections of a widely displaced left patellar sleeve fracture in an 11-year-old boy. This is also the injury repaired in the accompanying surgical video. Appreciate that there are indirect signs of fracture on the AP projection (patella alta), but fracture fragments are best visualized on the lateral projection.*

Figure 2. *Mid-sagittal MRI slices, proton density fat-saturated (A) and T1 (B) of the injury in Figure 1. Although not necessary for diagnosis, MRI can reveal size and number of osseous fragments (two in this case), the relationship of the patellar tendon to the osteochondral fragments, the location of chondral violation, and presence or absence of loose bodies.*

Nondisplaced patellar sleeve fractures can be treated nonoperatively in extension immobilization. Displaced injuries, those with articular incongruity, or those with accompanying extensor lag are indicated for open reduction and internal fixation (ORIF). There are multiple methods for operative fixation including tension band wires, absorbable intraosseous suture anchors, and transosseous nonabsorbable sutures. Regardless of the technique utilized, the goal of treatment is to restore the continuity and tension of the extensor mechanism.

Though relevant literature on this subject has been published, it is limited to case reports, case series, and review articles. Reports of operative treatment suggests that most patients return to full motion, regain active

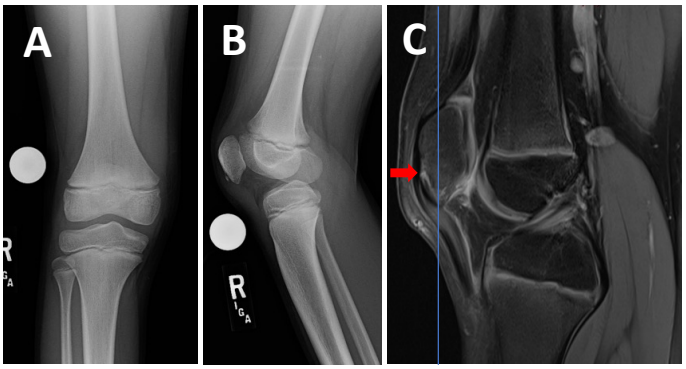

Figure 3. *A 9-year-old boy with a clinical history and exam consistent with a patellar sleeve fracture had equivocal AP (A) and lateral (B) radiographs. Sagittal (C) and coronal (D) MRI confirmed the presence of a fracture line at the inferior tip of the patella, adjacent bony edema, the patellar tendon attachment intact, and no displacement of articular surface. This injury was amenable to nonsurgical immobilization. The blue line denotes the slice location of the coronal view, and the red arrows denote the fracture line.*

knee extension, and have few complications regardless of the fixation method used.[3,7-12]

The purpose of this manuscript and accompanying video is to provide a detailed step-by-step description of an ORIF technique for a common pattern of patellar sleeve fracture: a widely displaced fracture pattern with small fragment of comminution at the inferior pole, treated with a transosseous suture technique.

Description of Method

Indications

Any discontinuity of the extensor mechanism with clinically apparent extensor insufficiency (inability to maintain a straight leg raise or ability to extend the knee but with extensor lag) should precipitate reduction and fixation. In cases where the extensor retinaculum of the knee is fully intact (i.e., no extensor lag) and fragments are

Figure 4. *An anterior midline incision is planned and will be extended proximally to visualize the quadriceps insertion. This is the case from Figure 1.*

nondisplaced (1–2 mm), nonsurgical treatment can be considered. Any articular incongruity should precipitate operative fixation.

Positioning

Supine positioning with a tourniquet is standard, and a bump can be placed under the ipsilateral hemipelvis to internally rotate a limb that rests in excessive external rotation. Tourniquet use will improve visualization of fracture fragments, although it may increase early postoperative pain. Ultrasonographic studies have shown that quadriceps excursion is equivalent with or without a tourniquet[13] so such a decision can be made independent of this consideration.

Operative Technique

Following a standard prep and drape, the patella and tibial tubercle are marked with a sterile pen with the leg in extension. A longitudinal midline incision is made from the mid-patella extending down to the mid-substance of the patellar tendon (Figure 4). Sharp dissection is carried down through the prepatellar bursa until fracture hematoma is visualized. This is extirpated and we recommend extending the incision proximally so as to easily visualize the quadriceps insertion on the cephalad aspect of the patella. This will facilitate suture passage later in the procedure.

After removal of fracture hematoma and copious lavage, fracture fragments can be identified. Depending on size, these may be amenable to provisional fixation with Kirschner wires under direct visualization, or alternatively, the surgeon can use a forceps to quickly effect a reduction and assess this under the lateral fluoroscopic image (Figure 5). Once the reduction is achieved, suture passage is planned. In this case, drill holes in the patella

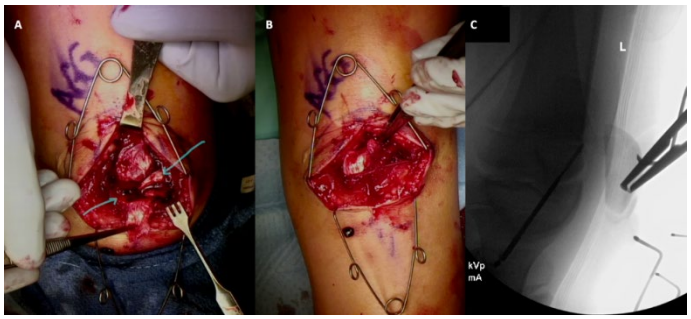

Figure 5. *Two small fracture fragments have been identified (A). The articular surface reduction cannot be easily visualized, so the surgeon is using a forceps to effect multiple candidate reductions (B) while assessing them on a lateral fluoroscopic image (C).*

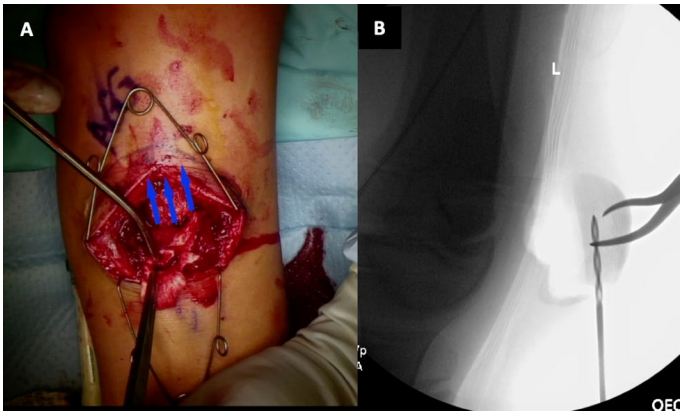

Figure 6. *Vertical drill hole sites have been marked with diathermy (A), and a 2.0 drill bit was advanced retrograde under fluoroscopic guidance to create three tunnels for later suture passage (B).*

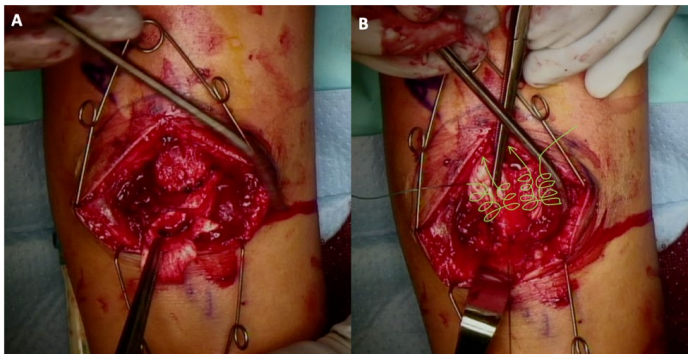

Figure 7. *Suture entry and exit sites have been marked with diathermy in the inferior pole osteochondral fragments (black dots, visible in medial fragment (A), and a Krackow running locked whip stitch is then placed in the fragments and cephalad half of the tendon (B). 0-Ethibond was used in this case, with four tails free.*

and entry/exit points of the suture in the osteochondral fragments are strategically placed to align and therefore obtain the planned reduction.

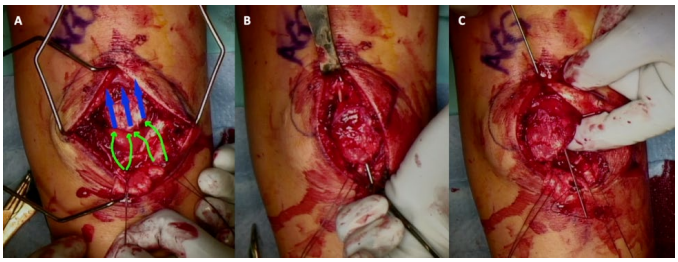

Figure 8. *Notice how the four tails of nonabsorbable suture (green arrows) will be passed retrograde through the three patellar drill holes (blue arrows, A). The importance of proximal visualization is emphasized, here demonstrating how the retrograde exit site of the drill bit proximally (B) will be used to visualize the antegrade location of suture passer placement (C). Here, a Hewson suture passer was used. Nonabsorbable suture was tied at the cephalad aspect of the patella.*

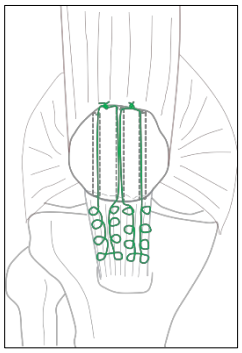

Figure 9. *Schematic representation of suture passage through vertical drill tunnels. Four strands of nonabsorbable suture are passed through three tunnels and tied on the cephalad patella. Image courtesy of Andrew G. Georgiadis, MD.*

Vertical drill holes are made with a 2.0- or 2.5-mm drill bit in anticipation of later suture passage, and a lateral fluoroscopic view during drilling ensures that the articular surface is not violated (Figure 6). Krackow-type sutures are placed running antegrade and retrograde in the patellar tendon with 0-Ethibond or another nonabsorbable braided suture (Figure 7). At this point, four suture tails are exposed, to pass through three available drill tunnels (Figure 8). The proximal exposure must visualize the drill bit's exit within the quadriceps to facilitate suture passage, so vertical sectioning of the tendon can be performed at each drill bit exit site.

A suture passer is then used to pass the sutures from distal to proximal so that the most medial and lateral tunnels each contain a single suture tail and the middle tunnel contains two. Other suture and tunnel configurations are possible, but it is difficult to create more than three or four drill tunnels in a pediatric patella and allow sufficient osseous bridging between each. The sutures are then tied to themselves on the superior patella under direct visualization (Figure 9). Orthogonal fluoroscopic

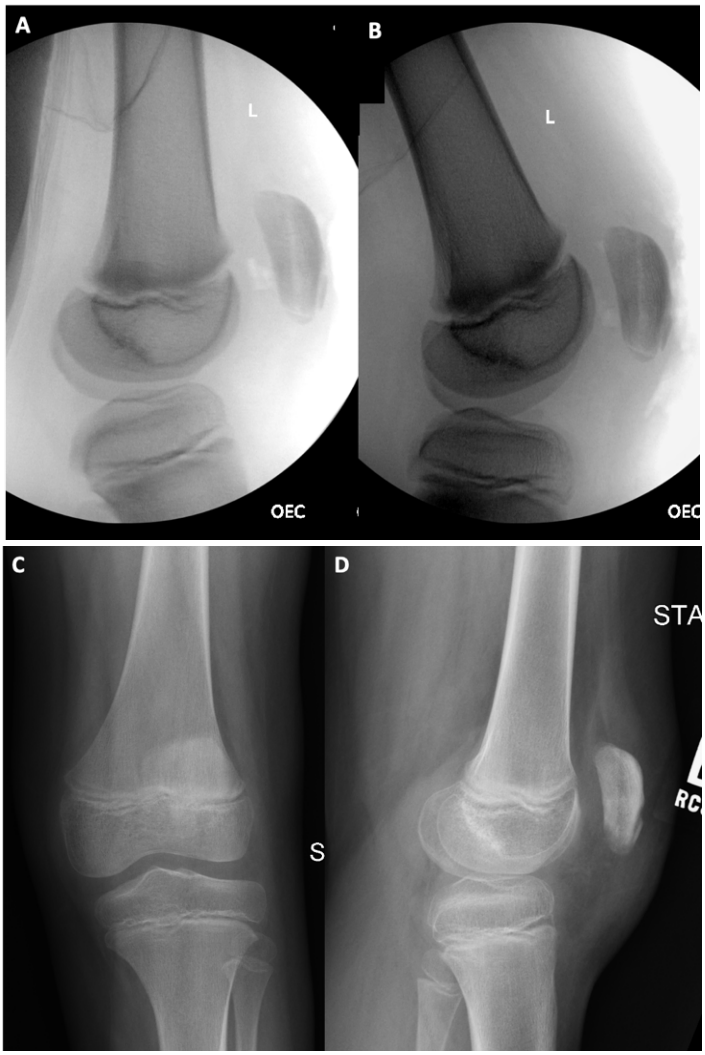

Figure 10. *After final fixation (A), stress examination was performed to 45 degrees of passive knee flexion (B). AP (C) and lateral (D) radiographs of the knee at 5 weeks postoperatively demonstrate maintained reduction, early osseous consolidation of fragments, and maintained patellar height.*

views can confirm reduction and alignment (Figure 10). We routinely perform knee range of motion to 45 degrees flexion to ensure adequate pullout strength has been achieved.

The extensor retinaculum can have a variety of injury patterns, and this can be closed with 0-Vicryl suture. We routinely repair the prepatellar bursa as a separate later. Subcutaneous and subcuticular closure then proceeds with absorbable monofilament. Patients may be weight-bearing as tolerated only while in a knee immobilizer or extension cast.

Postoperative Care

The repair will not be compromised by weight-bearing in extension, so this can be achieved with a removable brace (knee immobilizer, hinged knee brace), or in cases where compliance or cognition are under question, a long leg cast in extension. We avoid all active knee extension for 4–6 weeks regardless of immobilization. At 6 weeks, we begin active ROM under the direction of a physical therapist twice weekly, begin weight-bearing out of the brace, weaning from crutches, with a goal of achieving >90 degrees flexion motion by 10 weeks postoperatively. Some children will continue with therapy, including light plyometrics at 2.5–3 months and sport-specific rehabilitation at 3–4 months.

Tips and Pearls

Do not hesitate to extend the exposure proximally so as to visualize the passage of suture within the quadriceps tendon.

The assessment of reduction is usually by direct visualization of the osteochondral fragments at the undersurface of the patella (Figure 11). Once reduction is affected, the articular surface may be difficult or impossible to see directly, particularly if the medial and lateral retinacula are intact and obstructing vision. If direct visualization is nonexistent, but there is sufficient bone in the inferior pole to obtain an x-ray assessment, we recommend performing multiple fluoroscopic views in the lateral position. The surgeon can perform a "best guess" reduction with forceps, obtain an image, change the reduction, and reassess until it is satisfactory on the C-arm images (Figure 5). It has been our observation that self-retaining point-to-point tenacula seldom effect a satisfactory reduction unless bony fragments are large, in which case fixation technique may resemble that of an adult patellar body fracture.

If suture tunnels are used, as described in the accompanying video, we recommend "marking" the entry and exit points of the suture passage within the inferior pole fragments so that these points correspond to the vertical

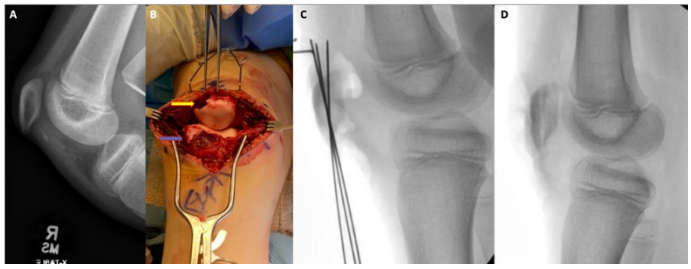

Figure 11. *A different case of a widely displaced right patellar sleeve fracture (A). Intraoperatively, the interdigitation of the osteochondral fragment (blue arrow) and the patella (yellow arrow) are readily visualized (B). In this case, provisional fixation was performed with Kirschner wires (C) and nonabsorbable suture was fixed in the inferior pole fragments via a Krackow whip stitch, then passed through the K-wire tunnels (D). Image courtesy of Jennifer C. Laine, MD.*

tunnels in the patella. If fragments are larger, as in Figure 11, they can be provisionally fixed with Kirschner wires and these tunnels can be used for suture passage.

We do not routinely perform a quantitative assessment of patellar height ratio after fixation, but unusual injury patterns have been described.[14] Therefore, we do recommend qualitatively evaluating patellar height via fluoroscopy before leaving the operating room.

We recommend using the image intensifier only in the lateral position throughout most cases and only checking an AP image at the terminus of the procedure or if this view aids in reduction assessment.

There is tremendous variation in fracture morphology, so the above fixation techniques should be adapted to each fracture pattern.

Comparison to Other Methods

There is no high-quality comparative literature on fixation technique for patellar sleeve fractures, likely because of the rarity of the injury and generally good outcomes reported. The technique described in this article details the use of transosseous tunnels and nonabsorbable suture fixation.

Tension-band wiring,[3,7,9,15] transosseous suture,[8,16] and suture anchors in combination with headless compression screws[12] have all been reported with good clinical

outcomes. Screw or anchor fixation has been advocated for larger osteochondral fragments.

One potential benefit of suture-only methods is the mitigation of prominent hardware, and we have observed good pullout strength to be achievable with suture as small as 0-Ethibond. Suture anchors may decrease the incision length if they obviate the need to directly visualize the cephalad aspect of the patella.

Summary

While rare, patellar sleeve fractures are the most common patellar injury in children, almost always occurring at the inferior pole. Diagnosis is key since osseous fragments are often small or nonexistent, so MRI may be indicated in some cases. Operatively treated patellar sleeve injuries can be reduced utilizing a variety of techniques. This technique article details the utilization of bone tunnels and suture for reduction. The described technique has the advantage of minimal equipment needs or fluoroscopy use but may not be appropriate for all fracture patterns.

References

1. Sponseller PD. In: Rockwood CA, Wilkins KE, Beaty JH, Kasser JR, editors. Rockwood and Wilkins' fractures in children. 5th ed. Philadelphia, PA: Lippincott Williams & Wilkins; 2001. p. xv, 1,244 pages.

2. Ray JM, Hendrix J. Incidence, mechanism of injury, and treatment of fractures of the patella in children. J Trauma. 1992 Apr;32(4):464-7. Epub 1992/04/01.

3. Houghton GR, Ackroyd CE. Sleeve fractures of the patella in children: a report of three cases. J Bone Joint Surg Br. 1979 May;61-B(2):165-8. Epub 1979/05/01.

4. Ogden JA. Radiology of postnatal skeletal development. X. Patella and tibial tuberosity. Skeletal Radiol. 1984;11(4):246-57. Epub 1984/01/01.

5. Zumstein M, Sukthankar A, Exner GU. Tripartite patella: late appearance of a third ossification center in childhood. J Pediatr Orthop B. 2006 Jan;15(1):75-6. Epub 2005/11/11.

6. Hunt DM, Somashekar N. A review of sleeve fractures of the patella in children. Knee. 2005 Jan;12(1):3-7. Epub 2005/01/25.

7. Hadlow AT, Medlicott PA. Bilateral simultaneous sleeve fractures of the patella in secondary hyperparathyroidism. Injury. 1987 Nov;18(6):417-8. Epub 1987/11/01.

8. Kaar TK, Murray P, Cashman WF. Transosseous suturing for sleeve fracture of the patella: case report. Irish journal of medical science. 1993 Apr;162(4):148-9. Epub 1993/04/01.

9. Gao GX, Mahadev A, Lee EH. Sleeve fracture of the patella in children. J Orthop Surg (Hong Kong). 2008 Apr;16(1):43-6. Epub 2008/05/06.

10. Gettys FK, Morgan RJ, Fleischli JE. Superior pole sleeve fracture of the patella: a case report and review of the literature. Am J Sports Med. 2010 Nov;38(11):2331-6. Epub 2010/09/03.

11. Lin SY, Lin WC, Wang JW. Inferior sleeve fracture of the patella. Journal of the Chinese Medical Association : JCMA. 2011 Feb;74(2):98-101. Epub 2011/03/01.

12. Boushnak MO, Moussa MK, Abed Ali AA, Mohsen ZH, Chamseddine A. Patellar Sleeve Fracture in an Eight-Year-Old Girl. Cureus. 2020 Sep 9;12(9):e10345. Epub 2020/10/17.

13. Herald J, Cooper L, Machart F. Tourniquet-induced restriction of the quadriceps muscle mechanism. Fact or fiction? J Bone Joint Surg Br. 2002 Aug;84(6):856-7. Epub 2002/09/05.

14. Sidharthan S, Schlichte LM, Green DW, Scher DM, Fabricant PD. Bifocal Patellar Tendon Avulsion Fractures in Children and Adolescents: Diagnosis and Treatment Considerations for a Unique Injury Pattern. Arthrosc Sports Med Rehabil. 2021 Feb;3(1):e97-e103. Epub 2021/02/23.

15. Bruijn JD, Sanders RJ, Jansen BR. Ossification in the patellar tendon and patella alta following sports injuries in children. Complications of sleeve fractures after conservative treatment. Arch Orthop Trauma Surg. 1993;112(3):157-8. Epub 1993/01/01.

16. Bailey MEA, Wei R, Bolton S, Richards RH. Paediatric injuries around the knee: Bony injuries. Injury. 2020 Mar;51(3):611-9. Epub 2020/02/19.